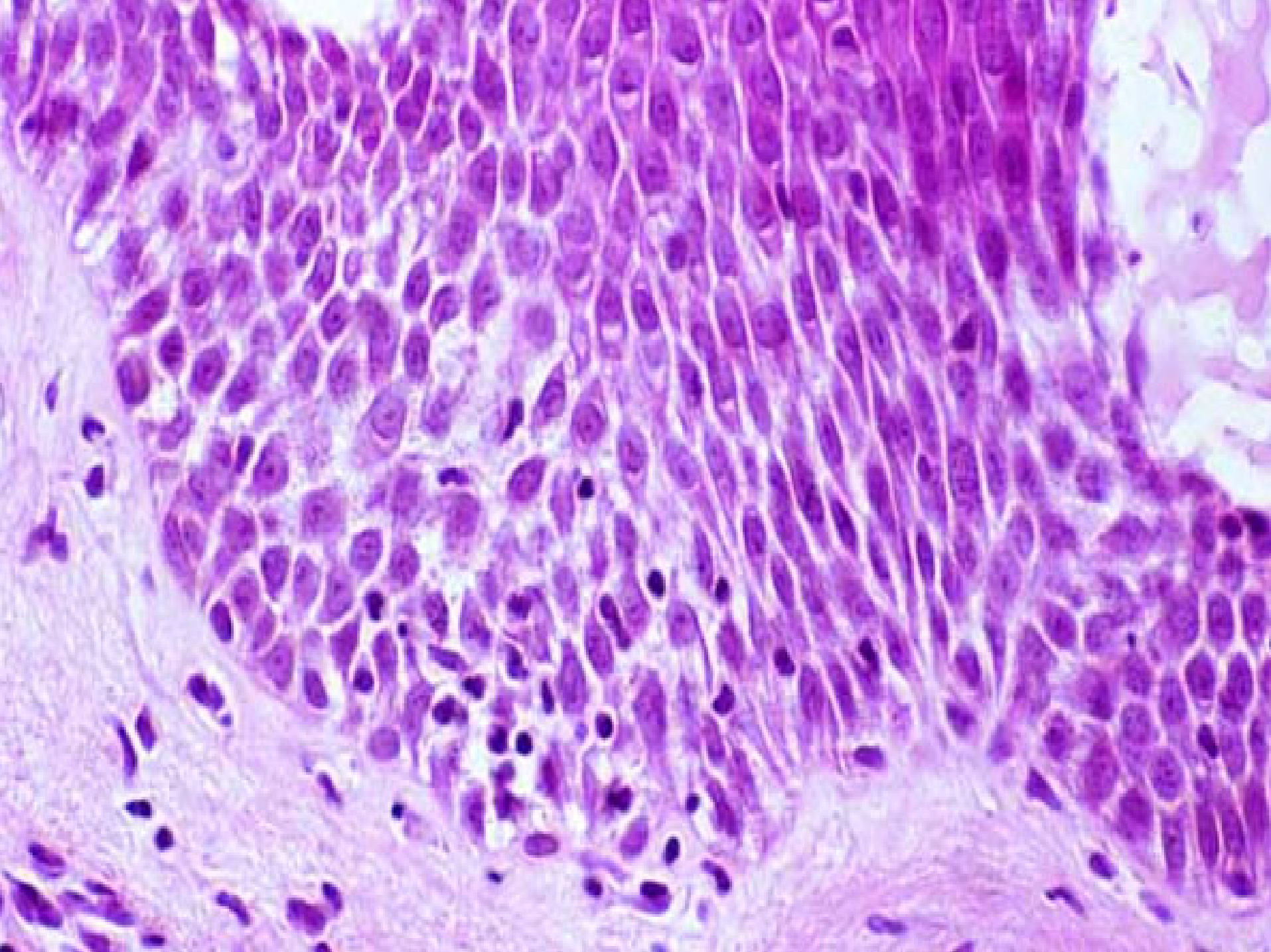

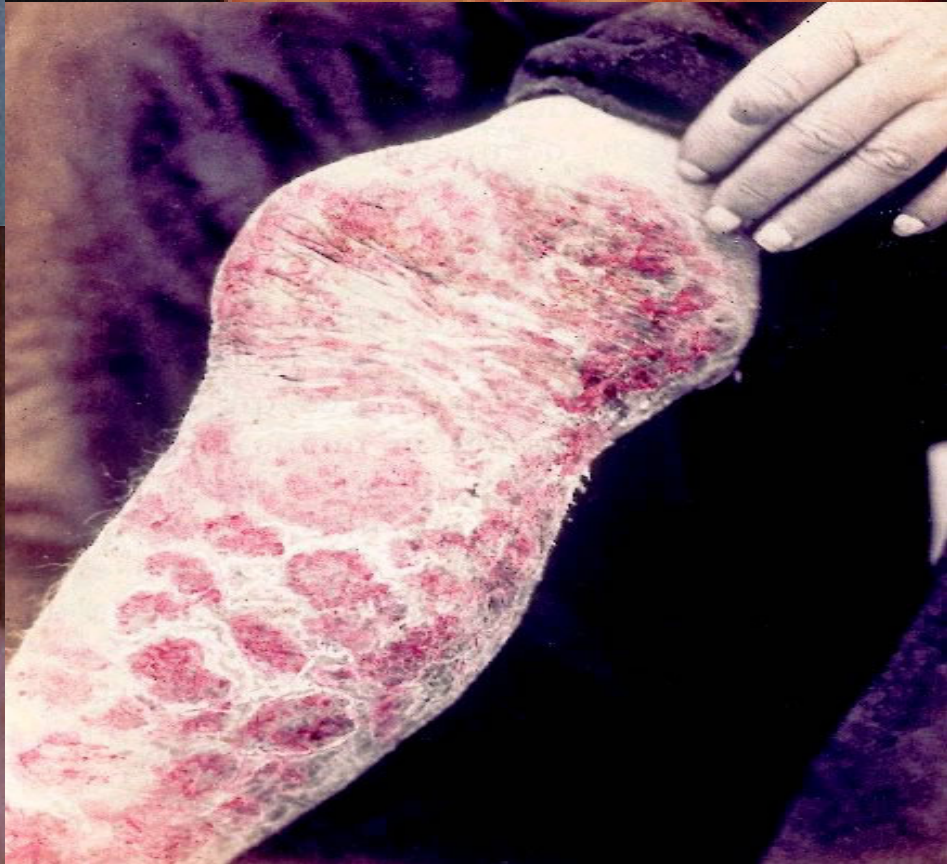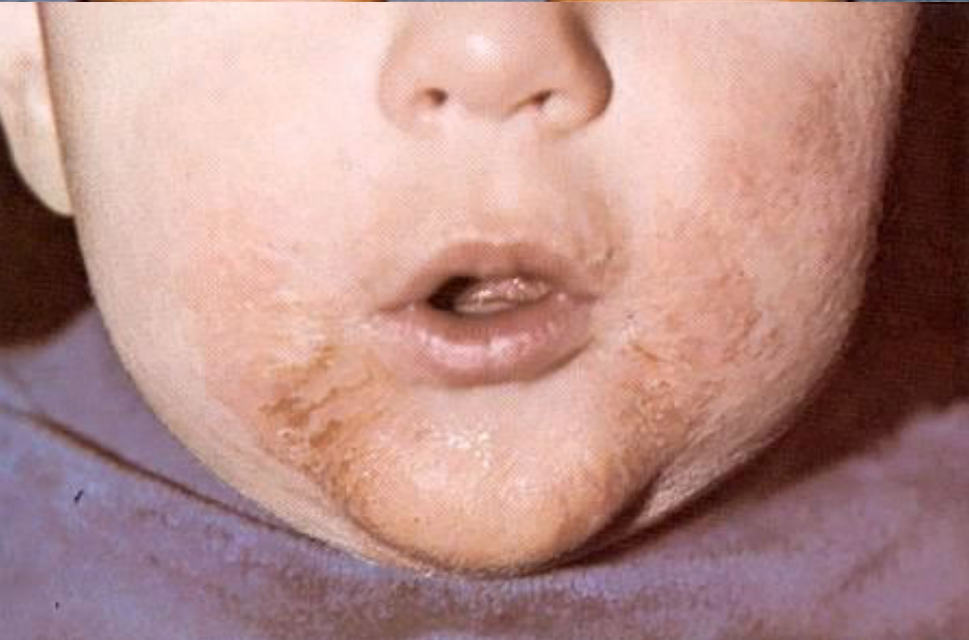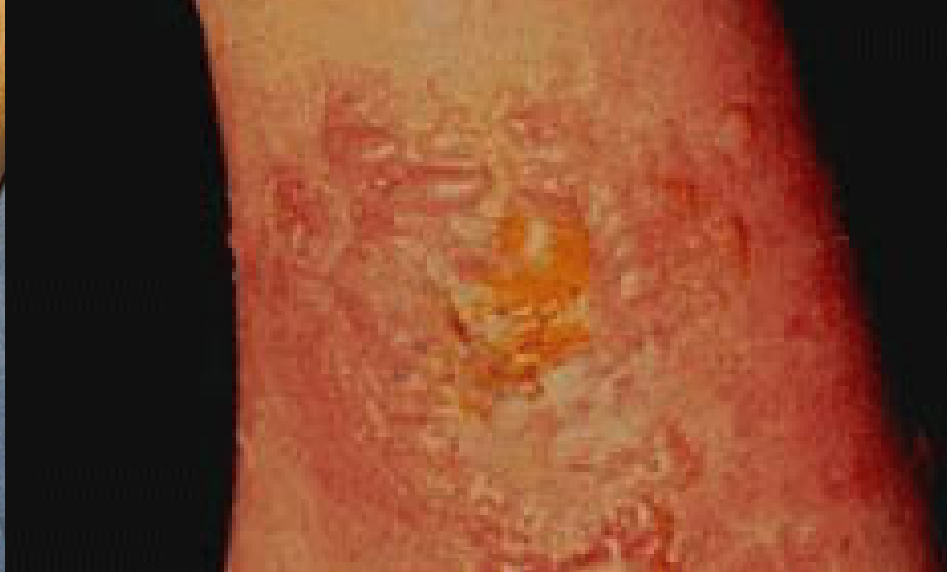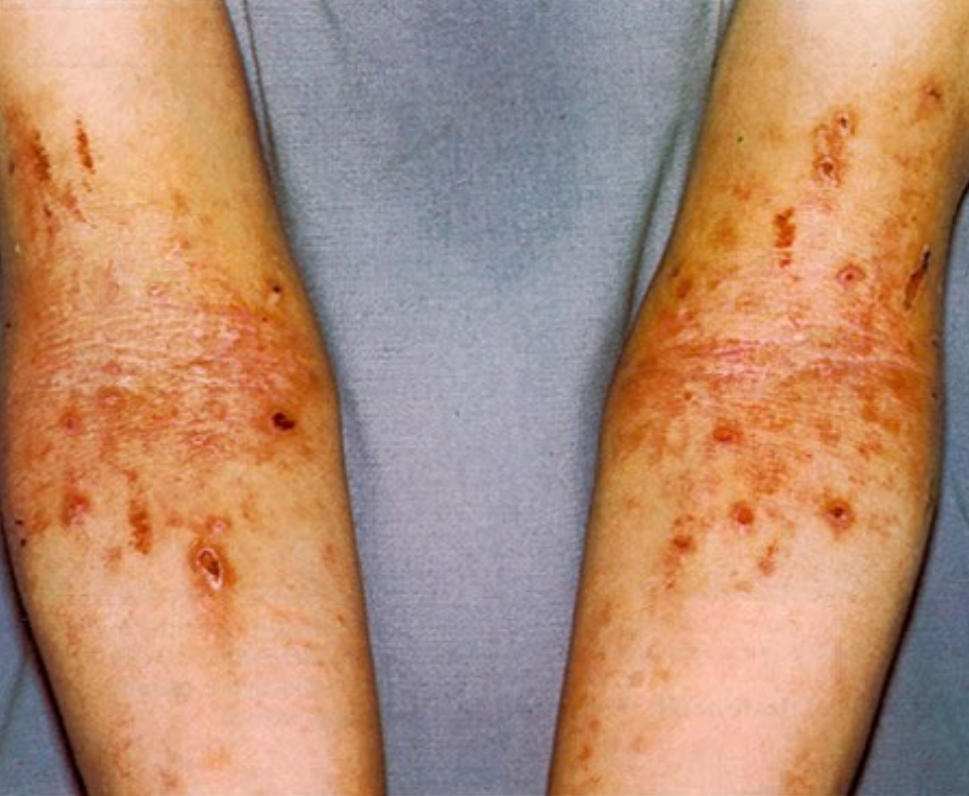# Spongiotic Dermatitis- Can We Be More Specific?

Paul K. Shitabata, M.D.

Dermatopathologist

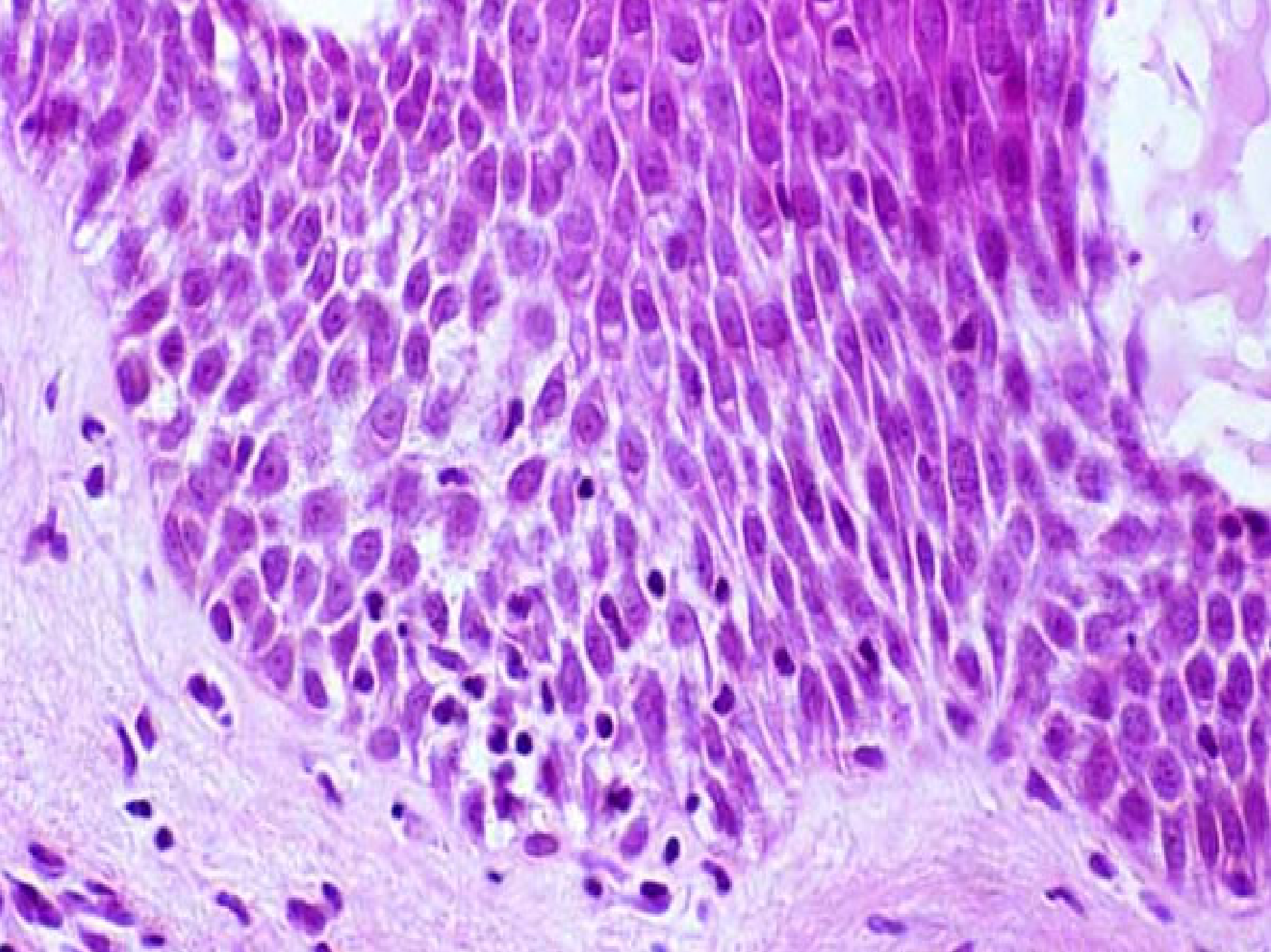
APMG



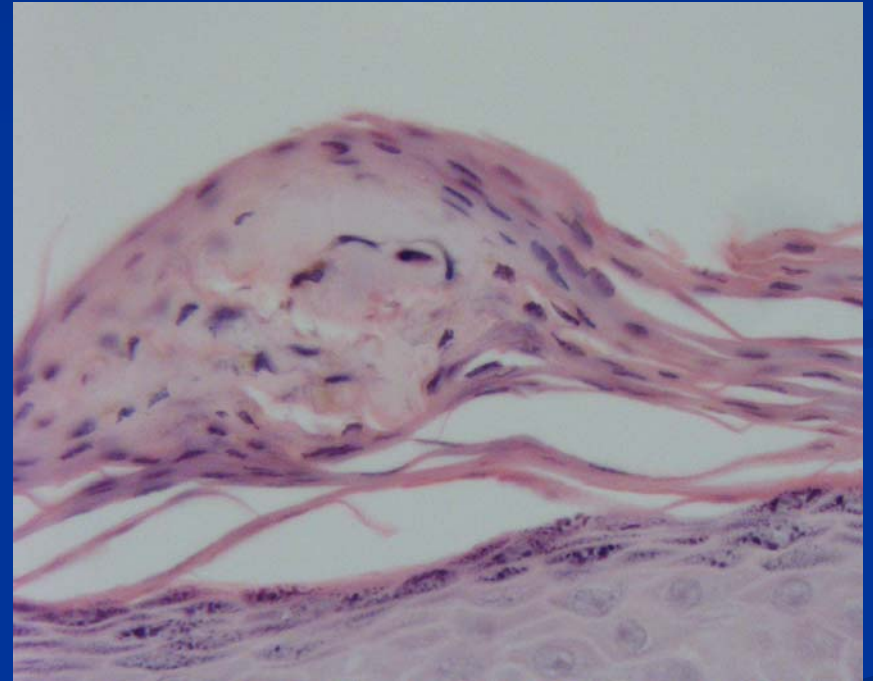
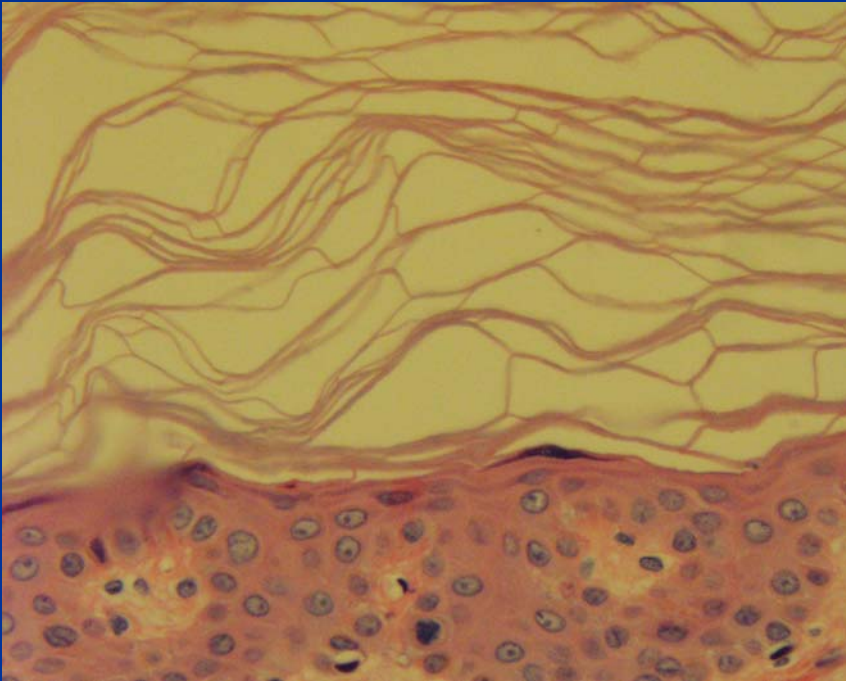
# **Eczema-What Does it Mean?**




# Spongiotic Dermatitis- What Does it Mean?



# Parakeratosis



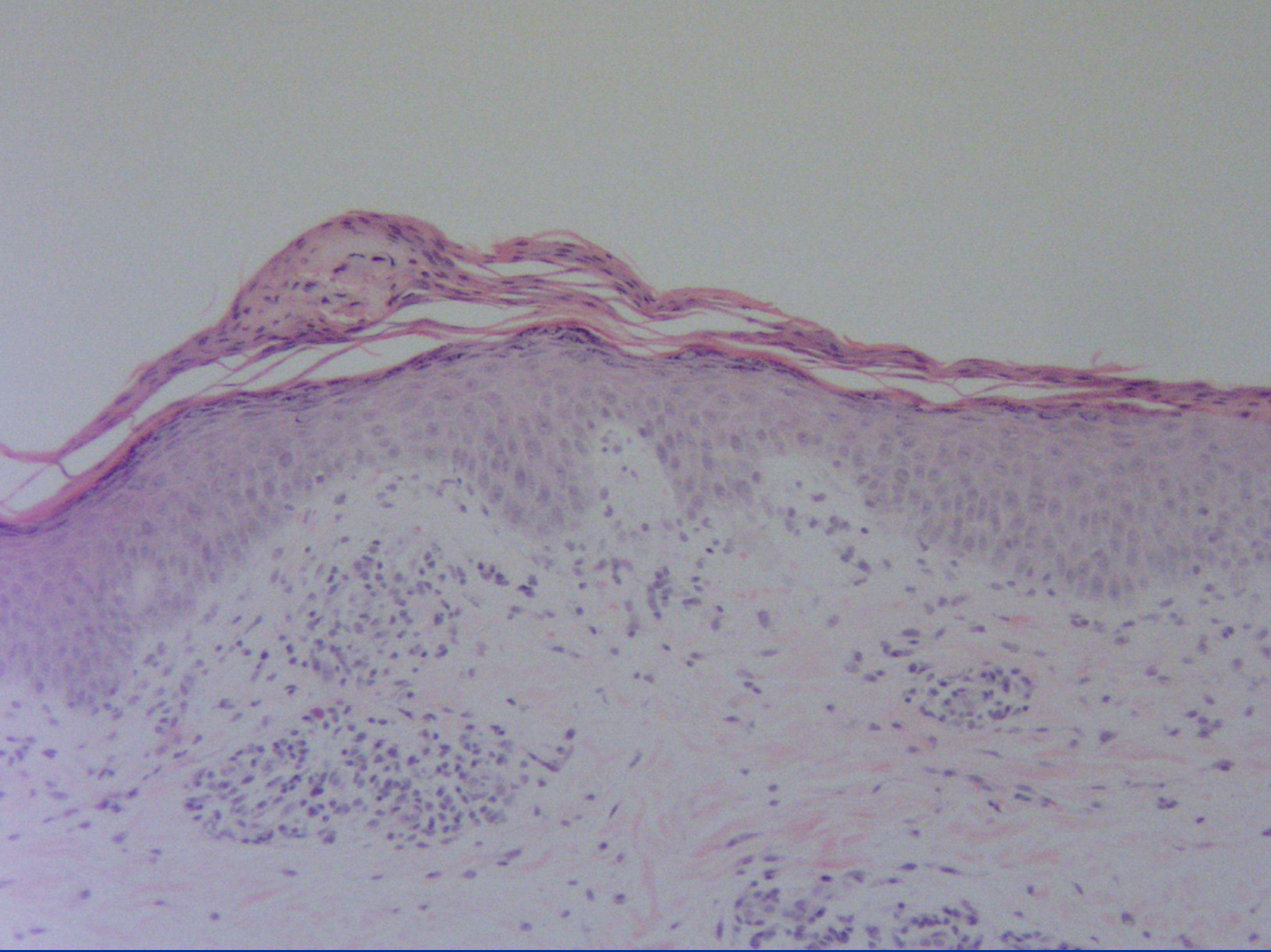
Follicle



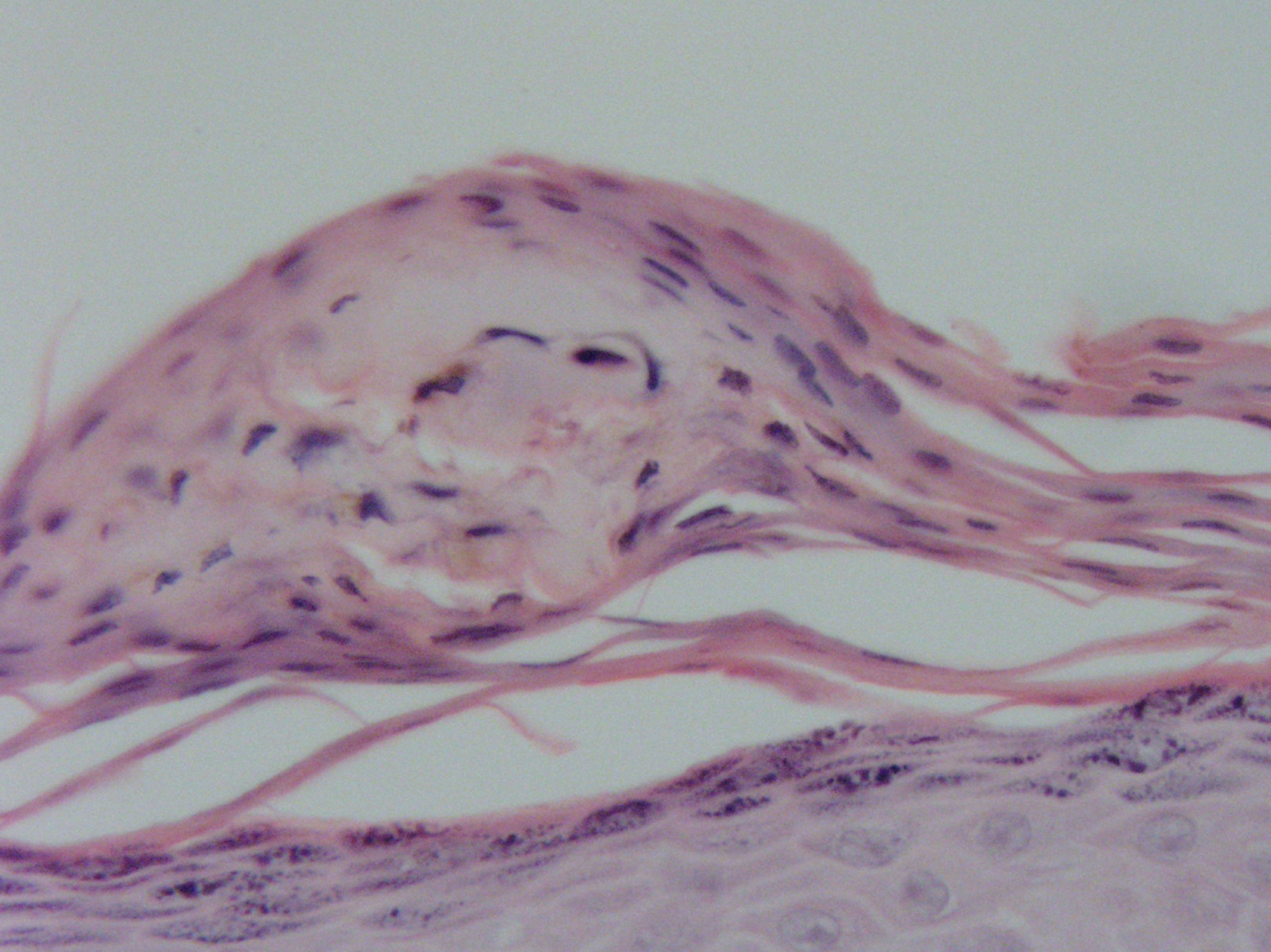
Scale

Inflammatory Cell Type

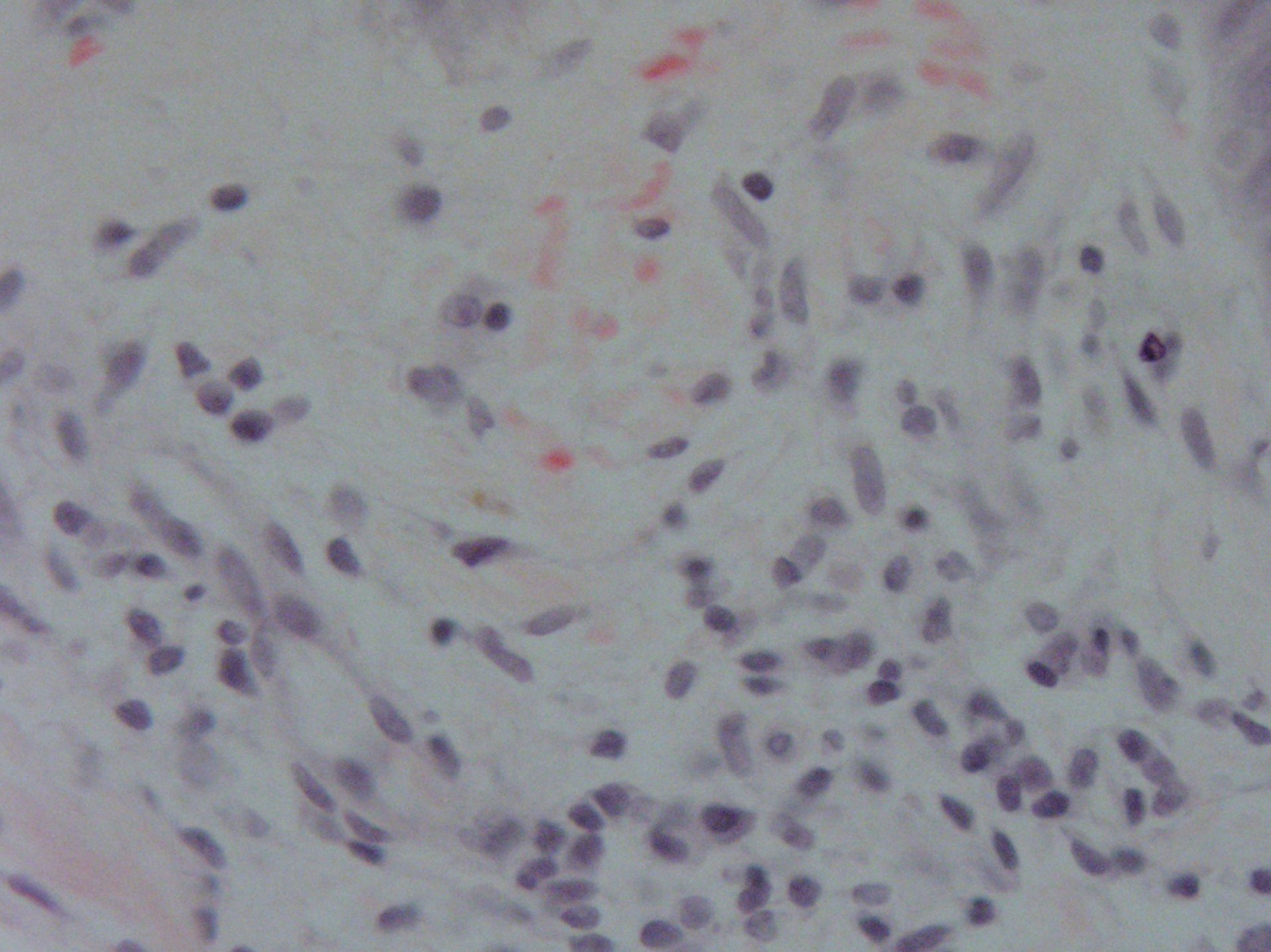













# Pityriasis Rosea



Follicle

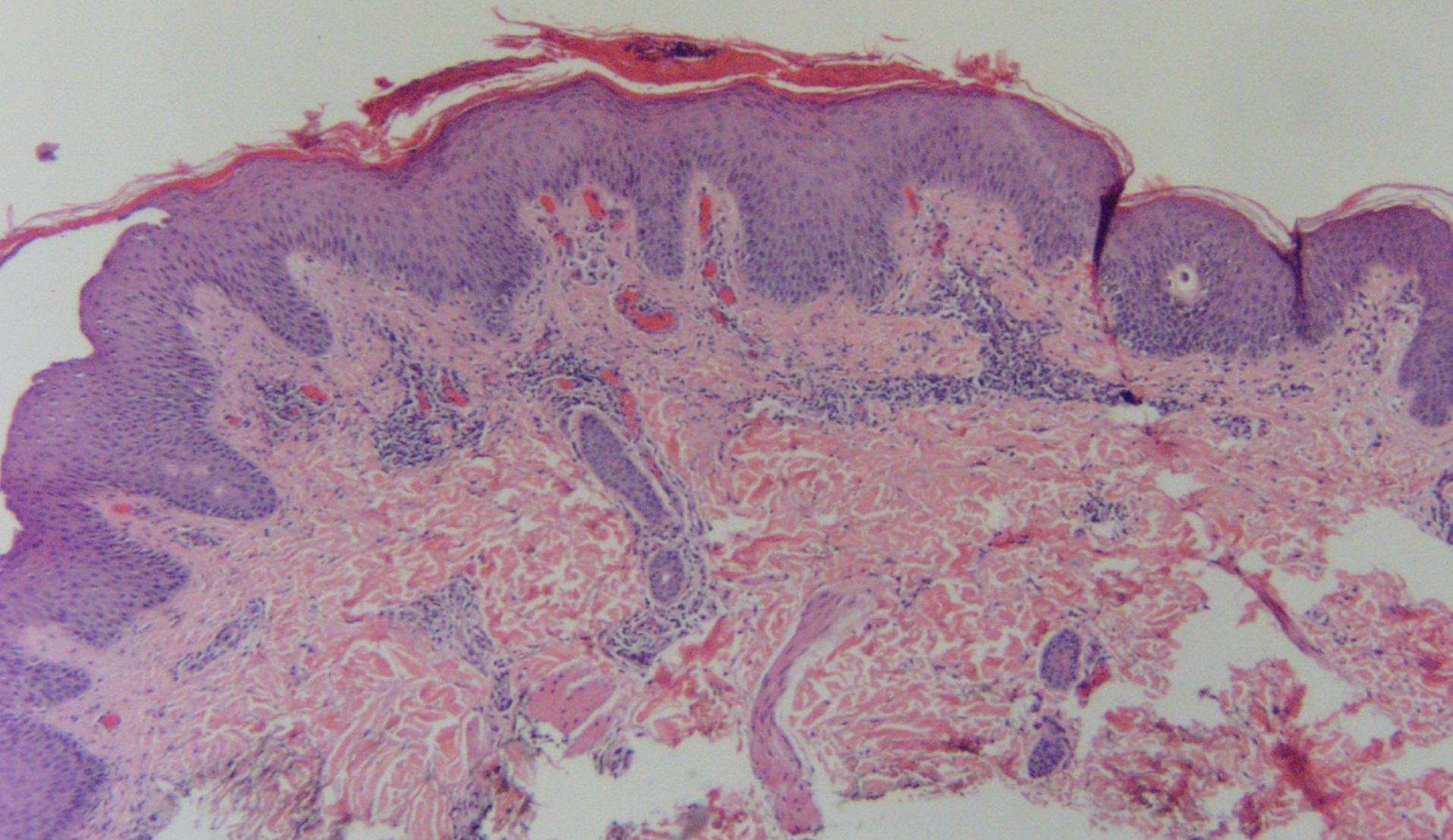


Scale

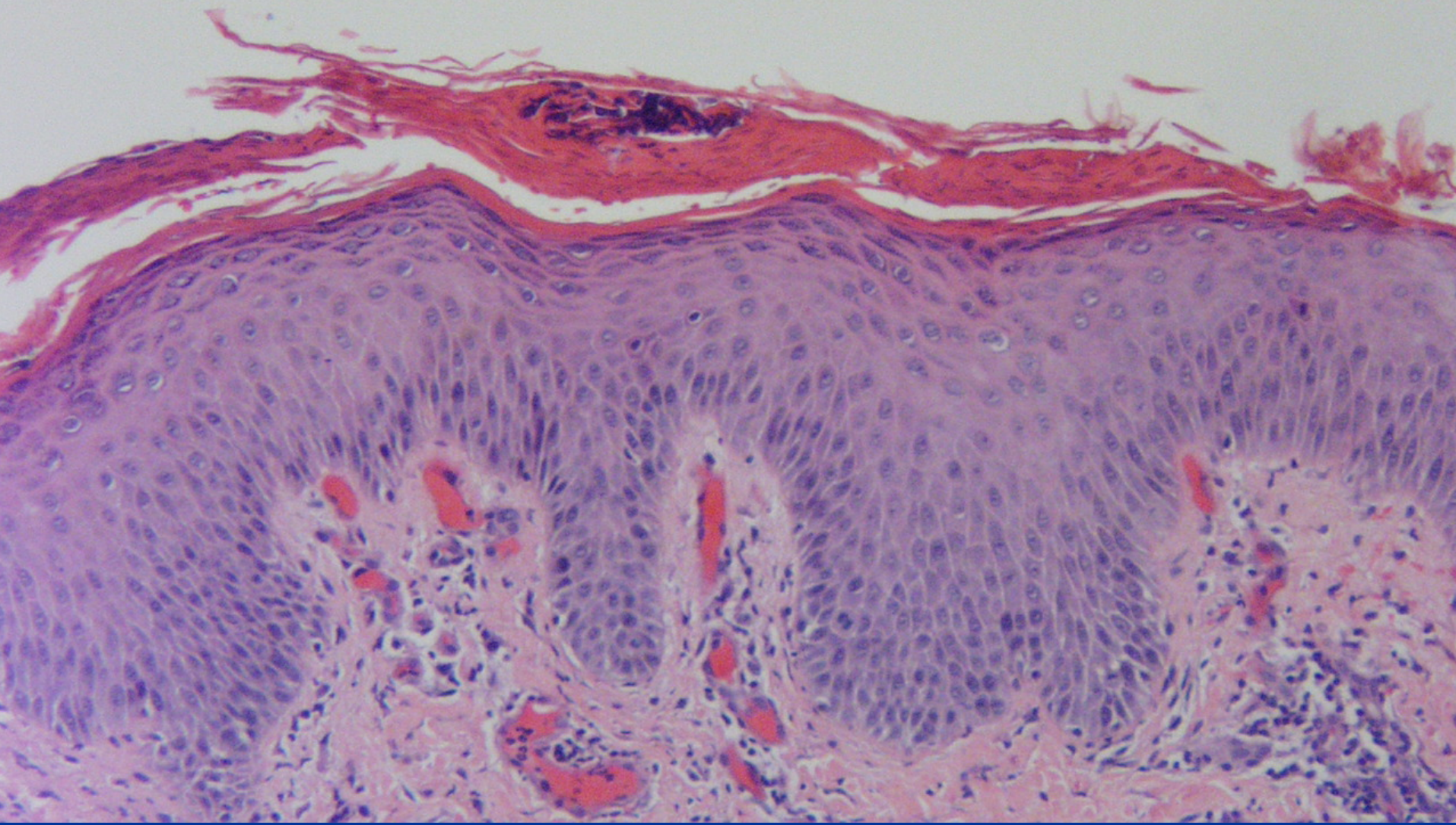
Inflammatory Cell Type

# Focus

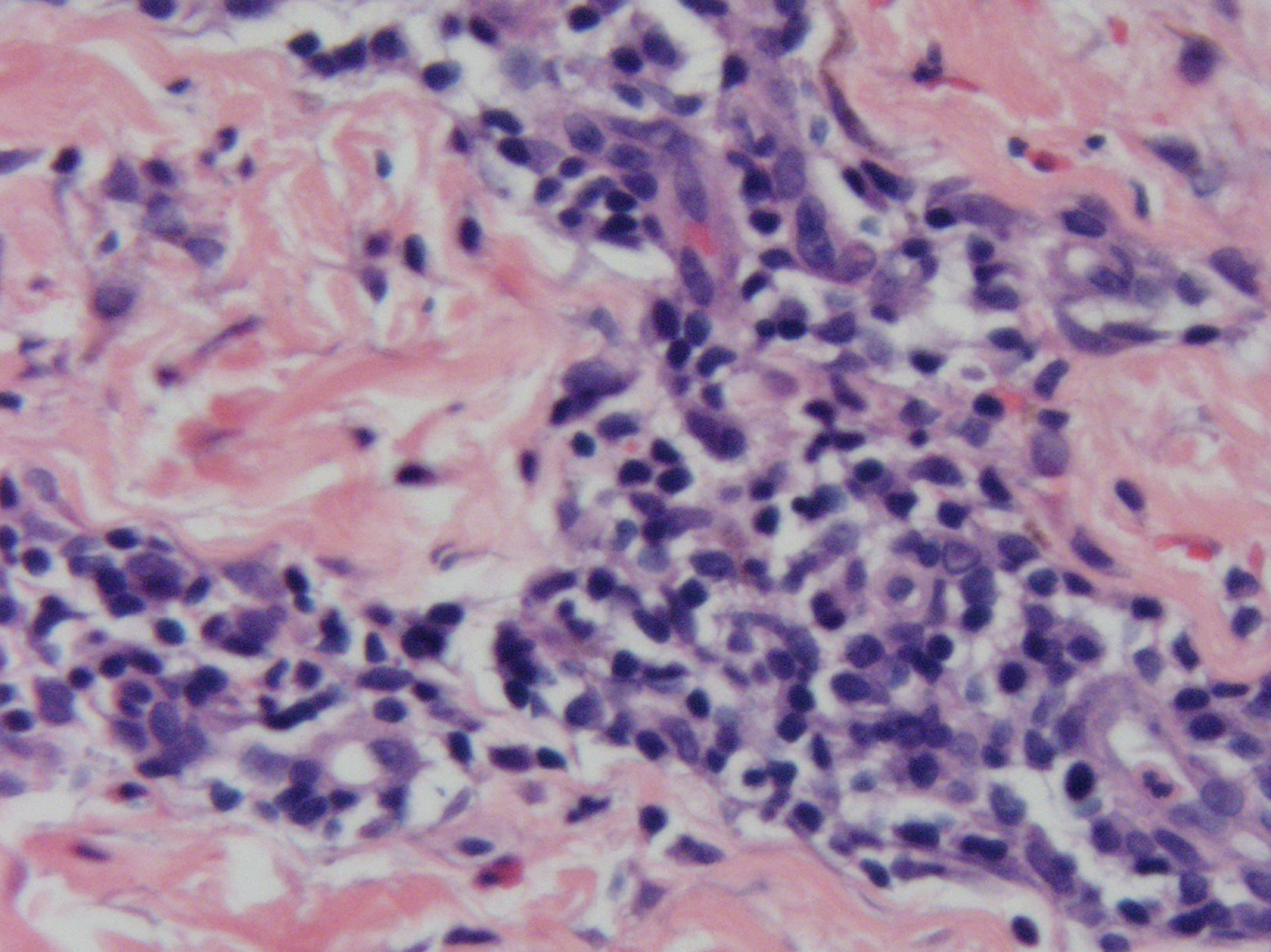
- Confluent parakeratotic scale
- Extravasated rbc's in papillary dermis
- Lack of capillary tortuosity












# Seborrheic Dermatitis

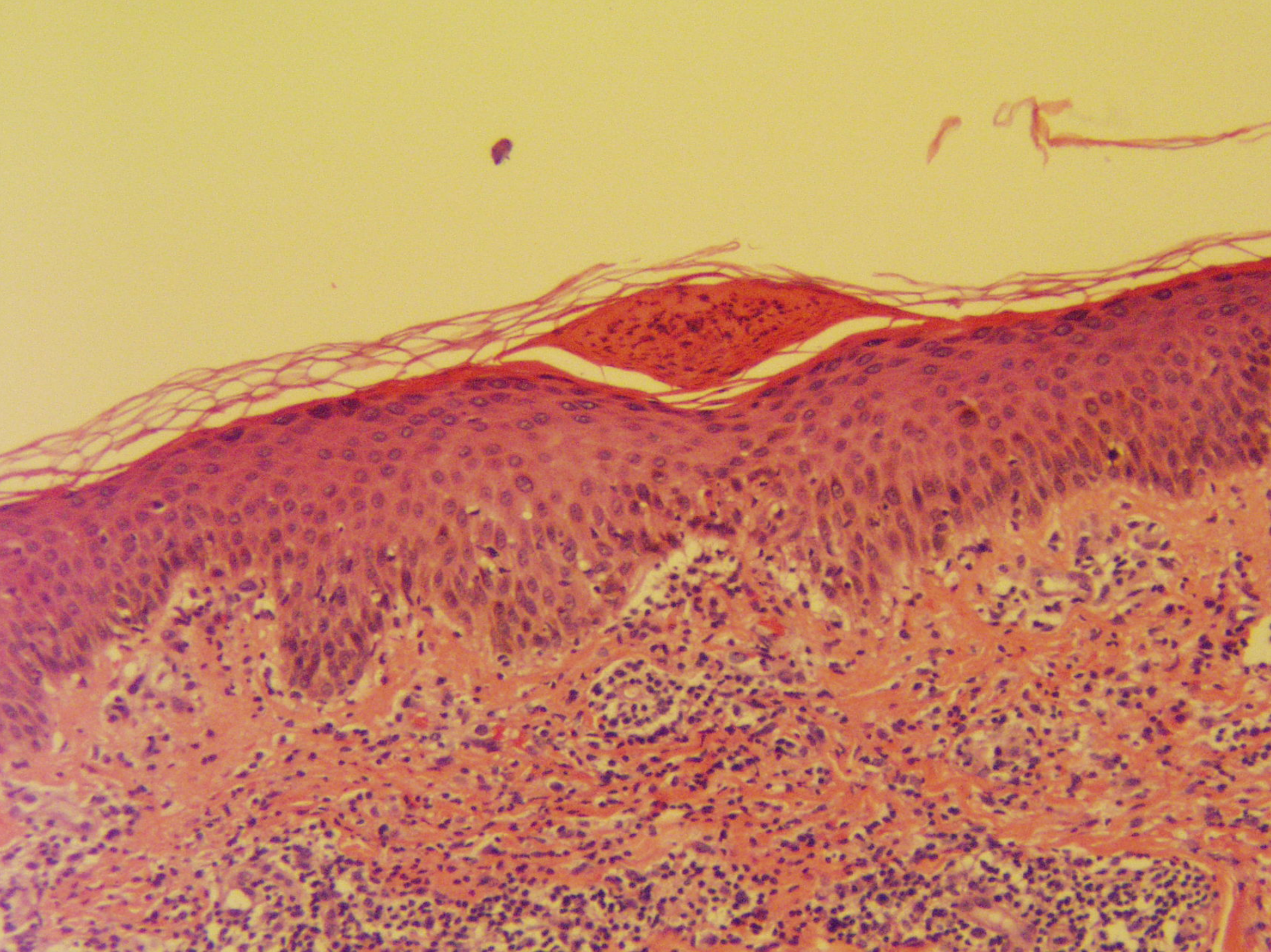
# Follicle



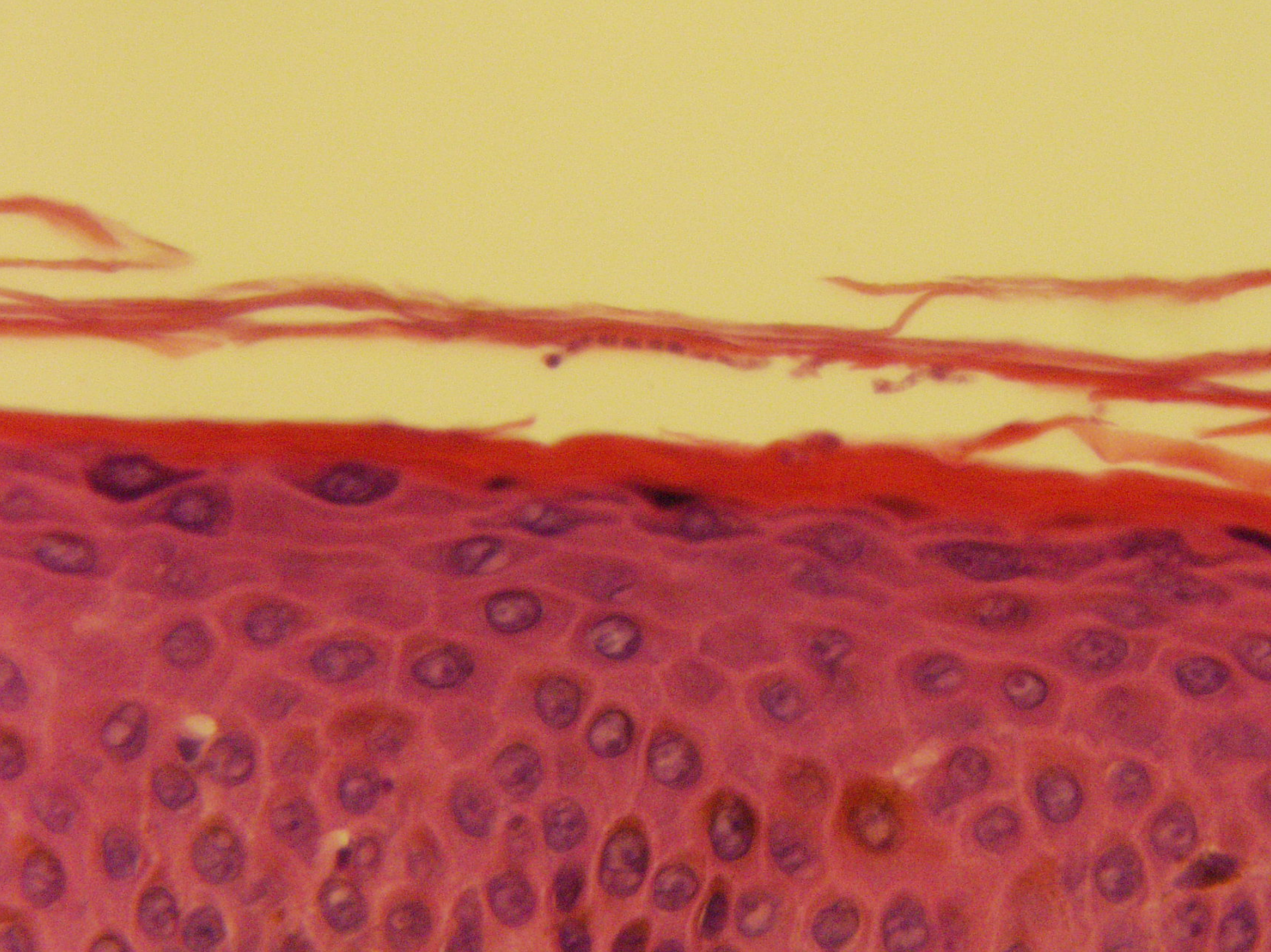
# Focus

- Parakeratosis at infundibular ostia
- Occasional neutrophils
- Exclude dermatophytosis










# Dermatophyte

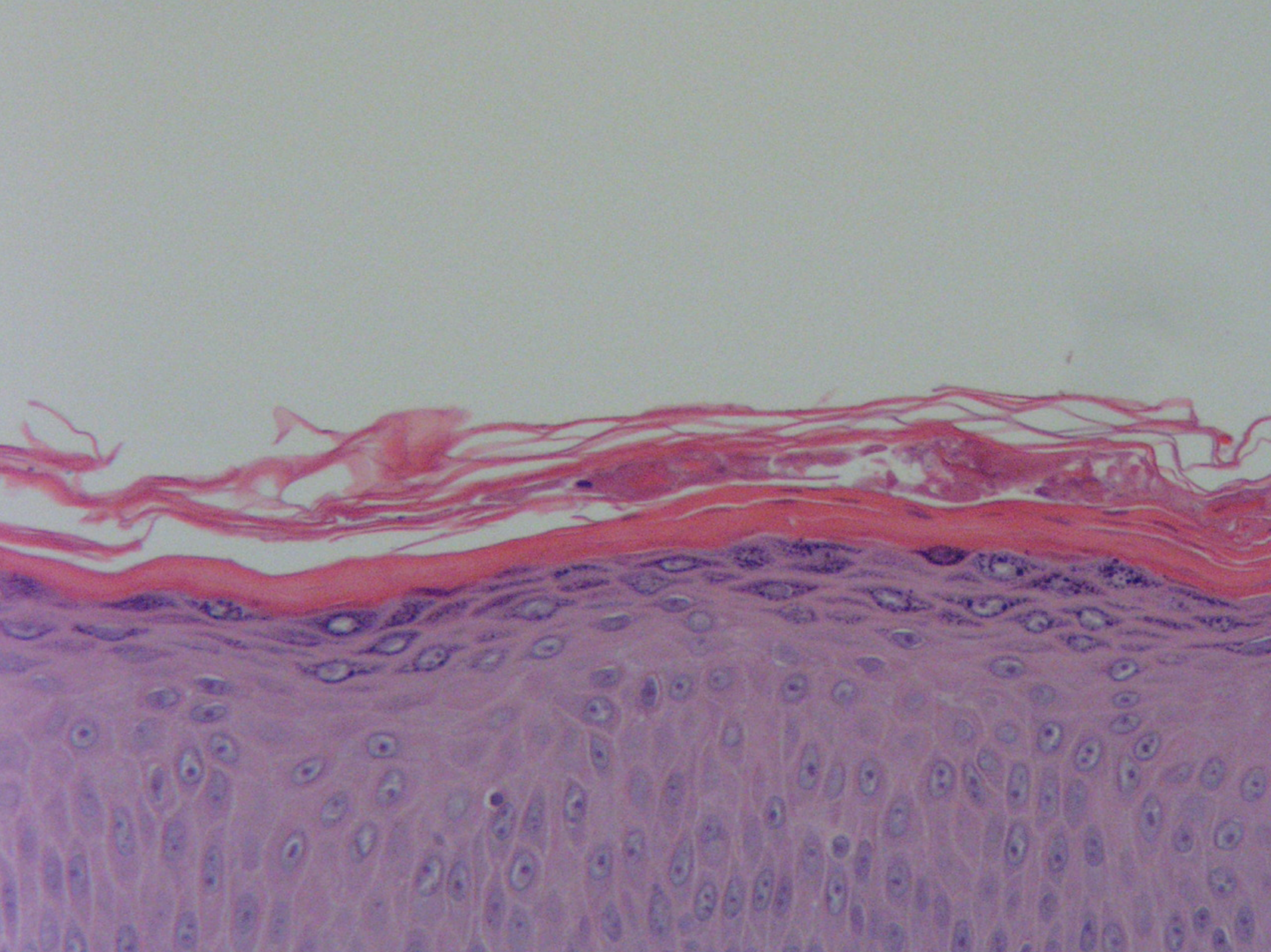
Follicle



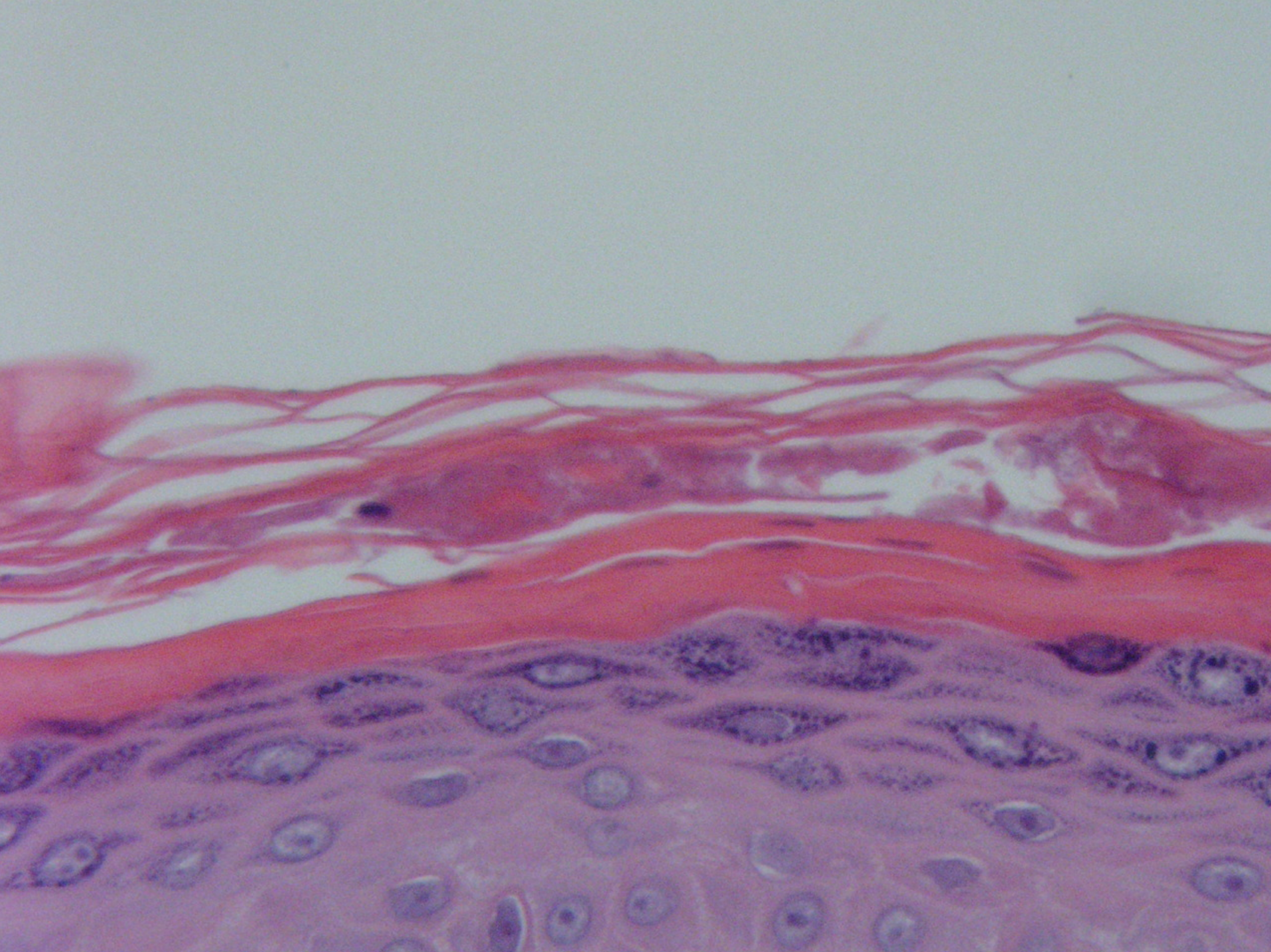
Scale

Inflammatory Cell Type

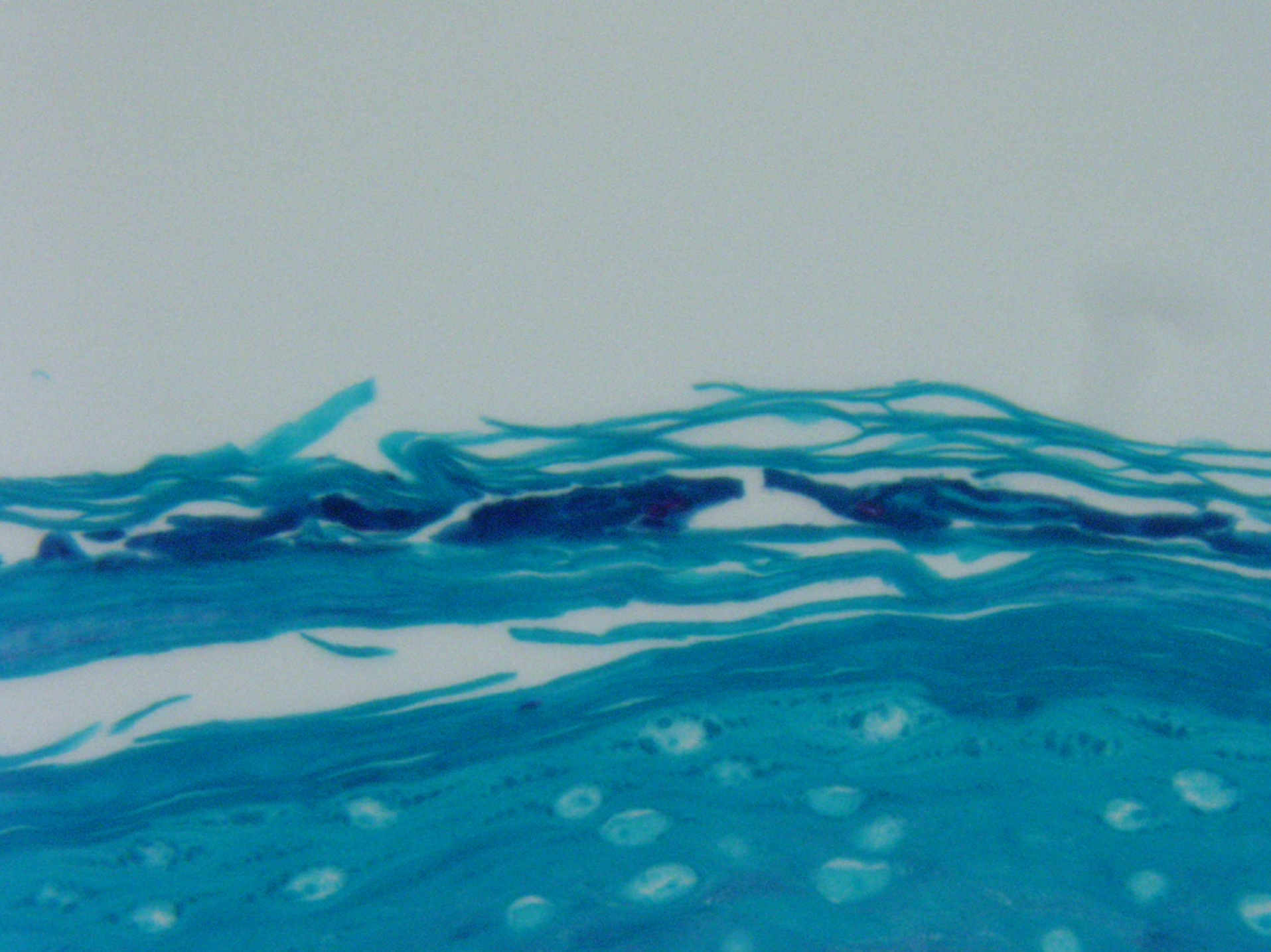








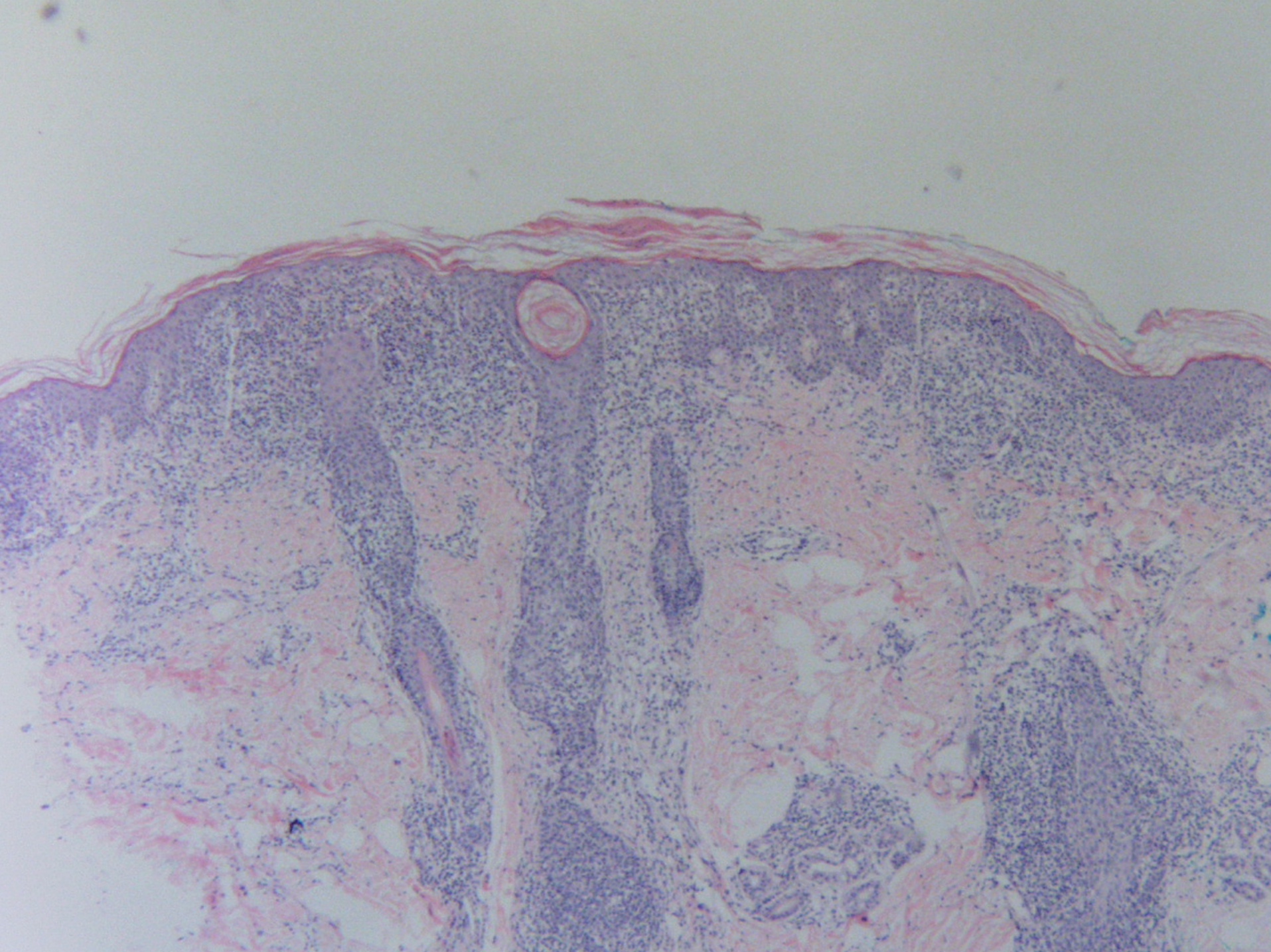




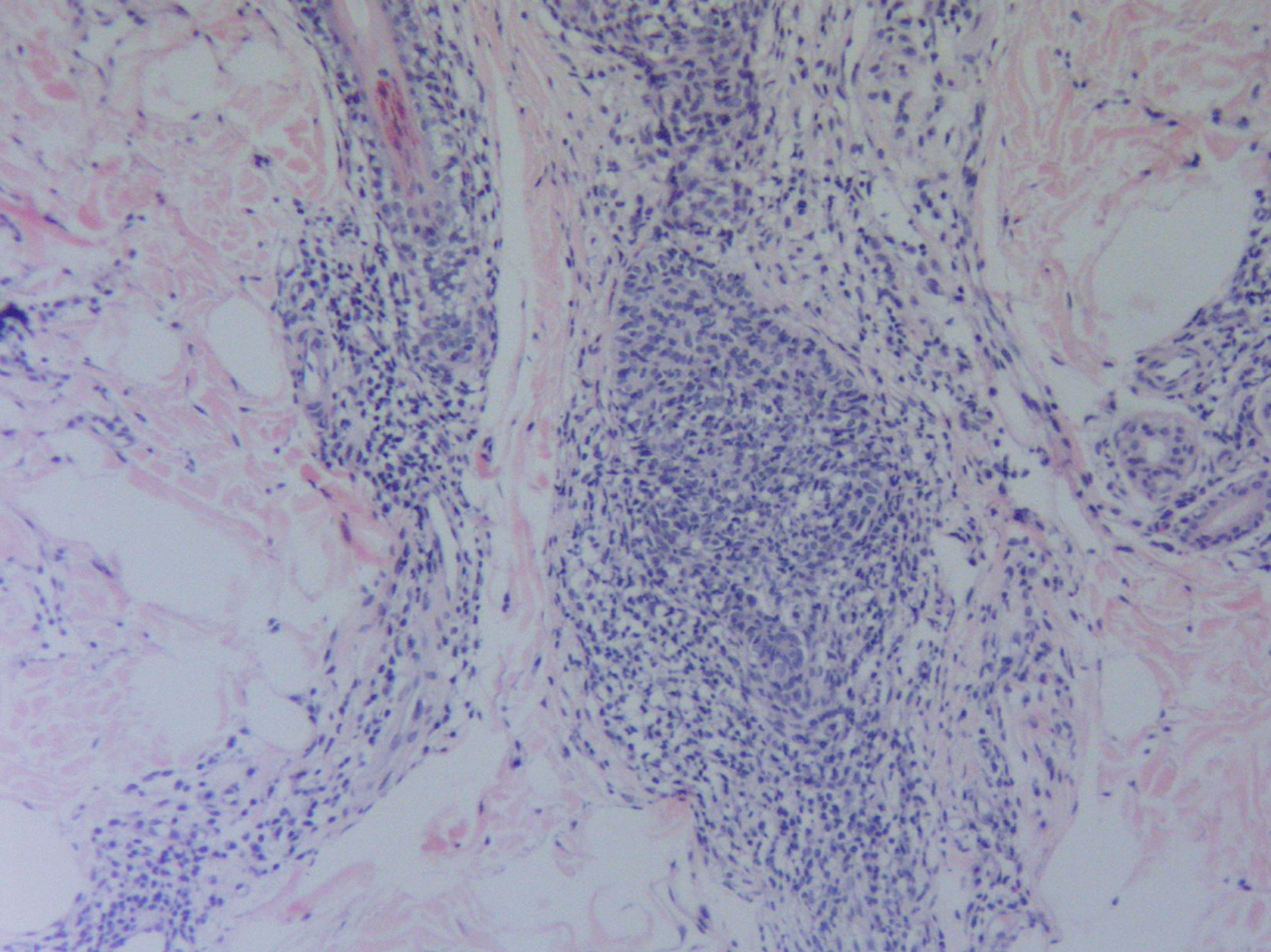


# Focus

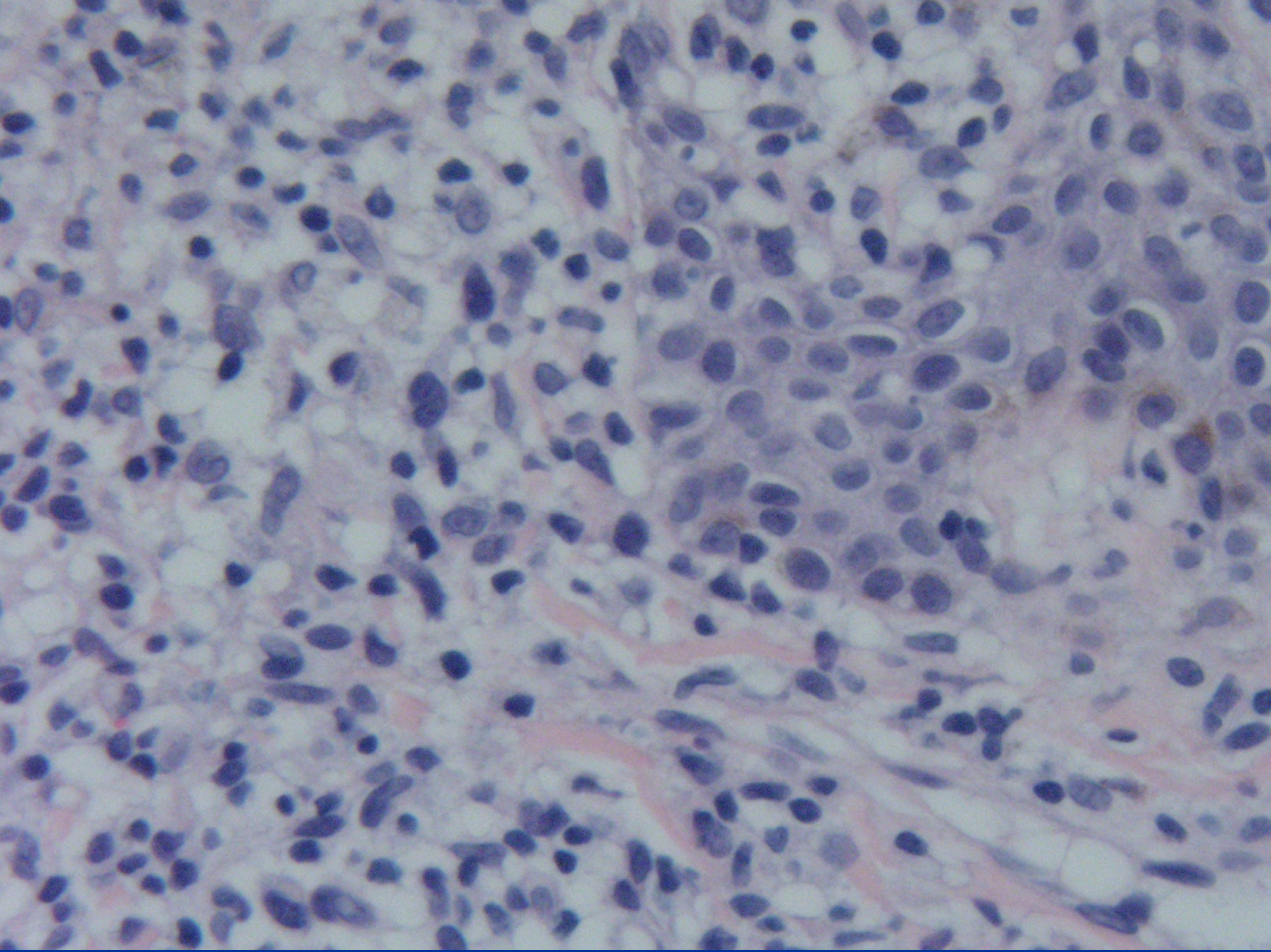
- Neuts in the horn
- Sandwich sign
- Specificity of changes questioned



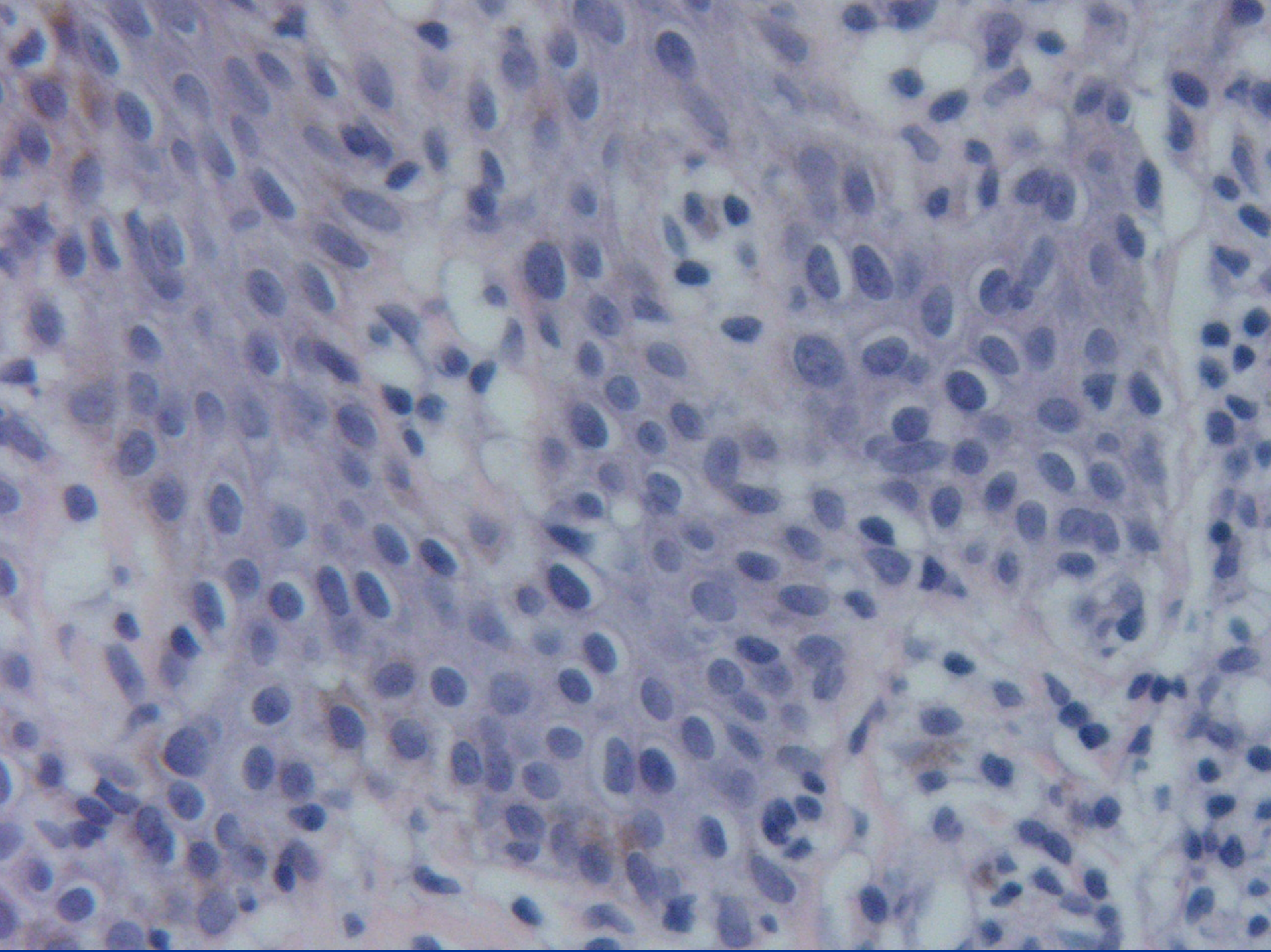













# Lichen Striatus



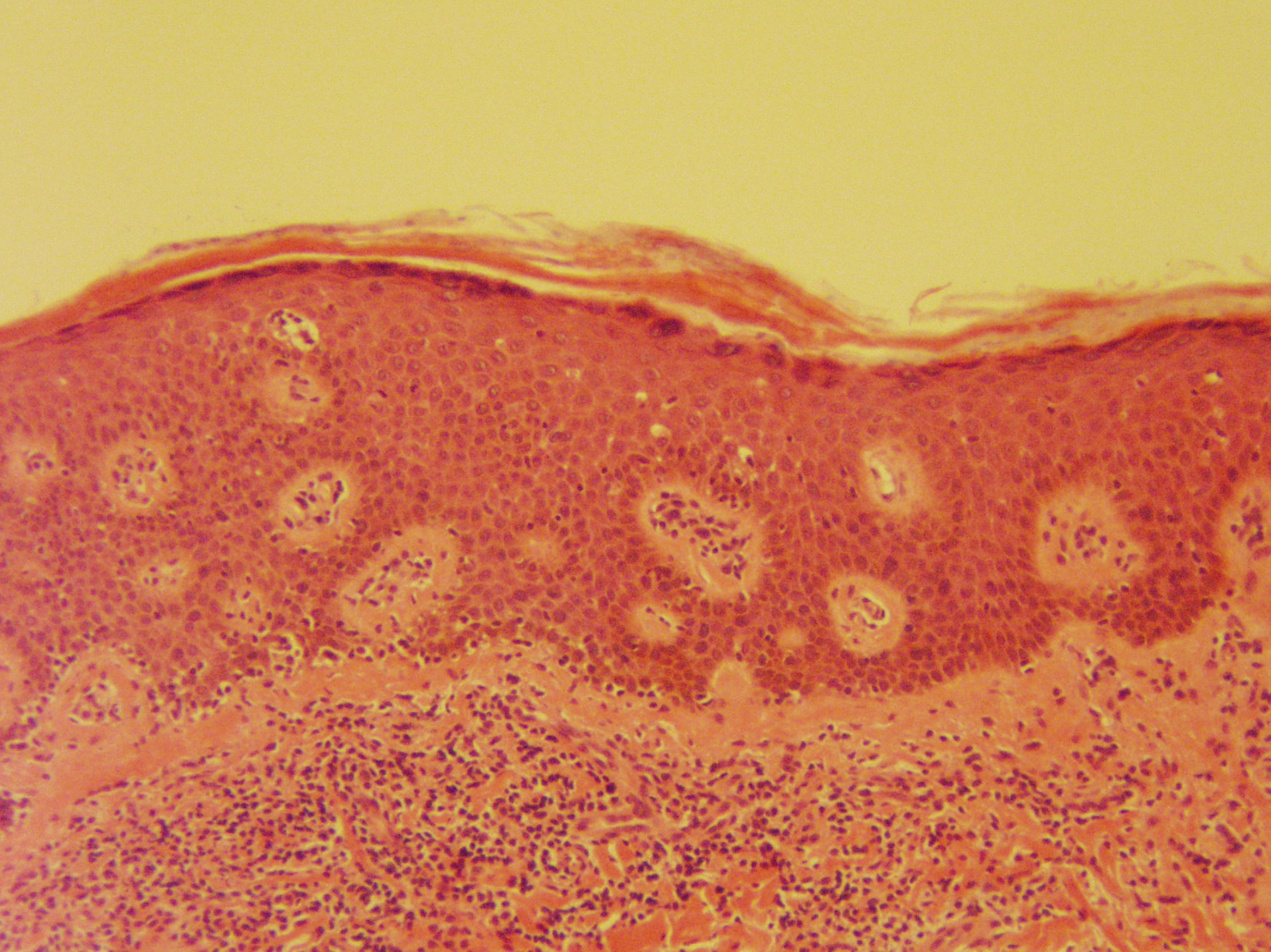
# Follicle



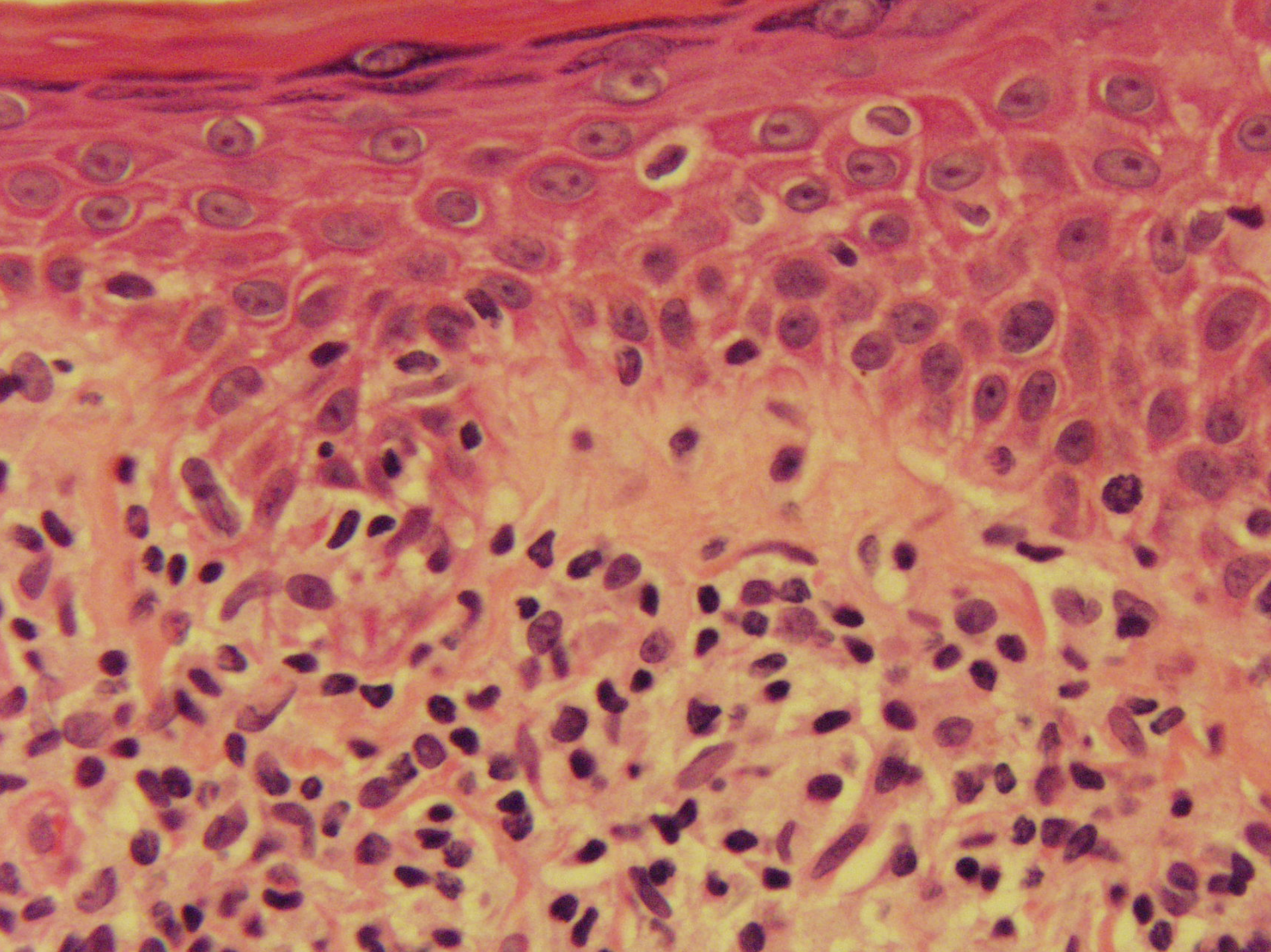
# Focus

- Psoriasiform dermatitis
- Lichenoid infiltrate
- Superficial and deep perivascular and periadnexal

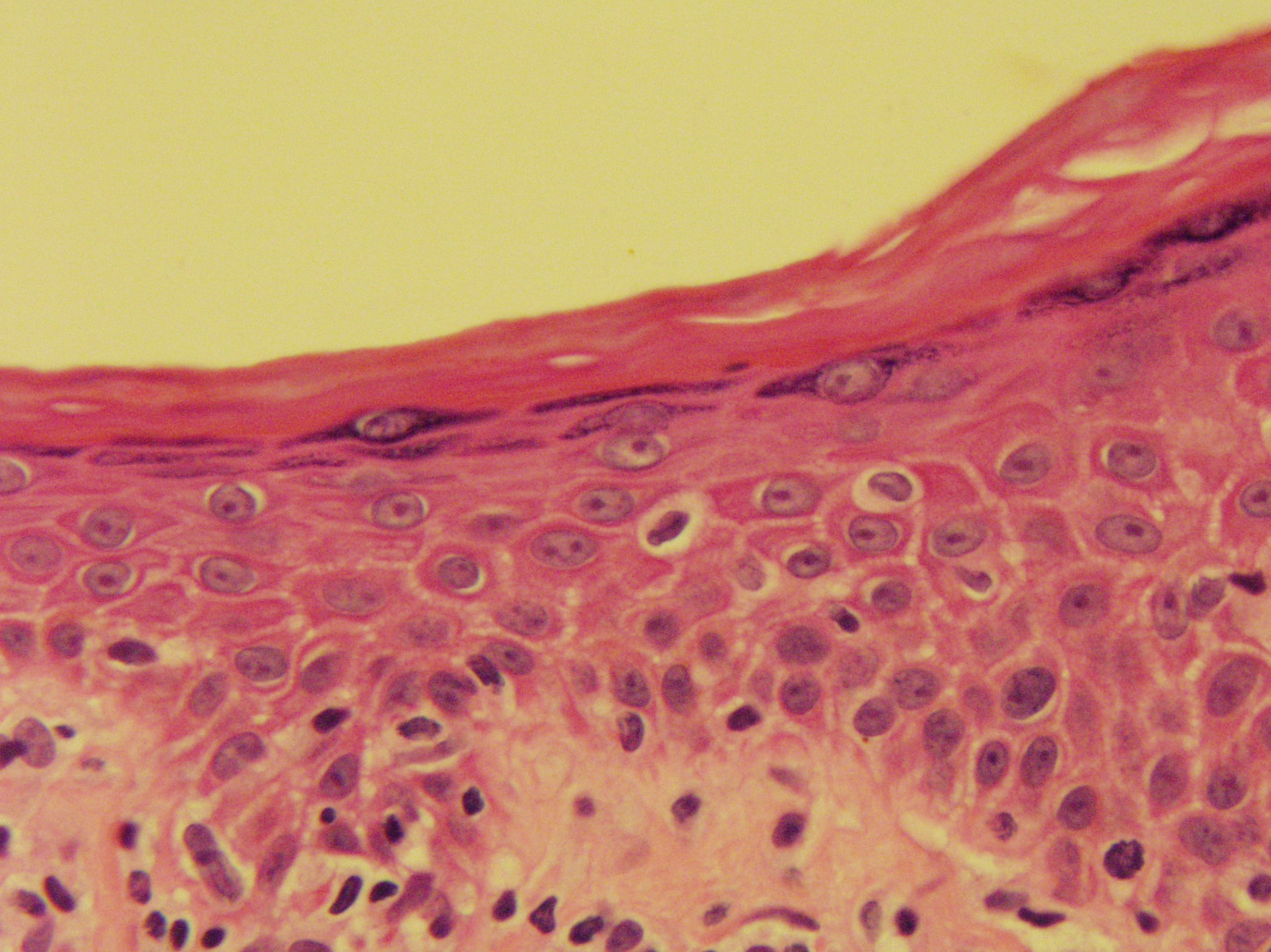




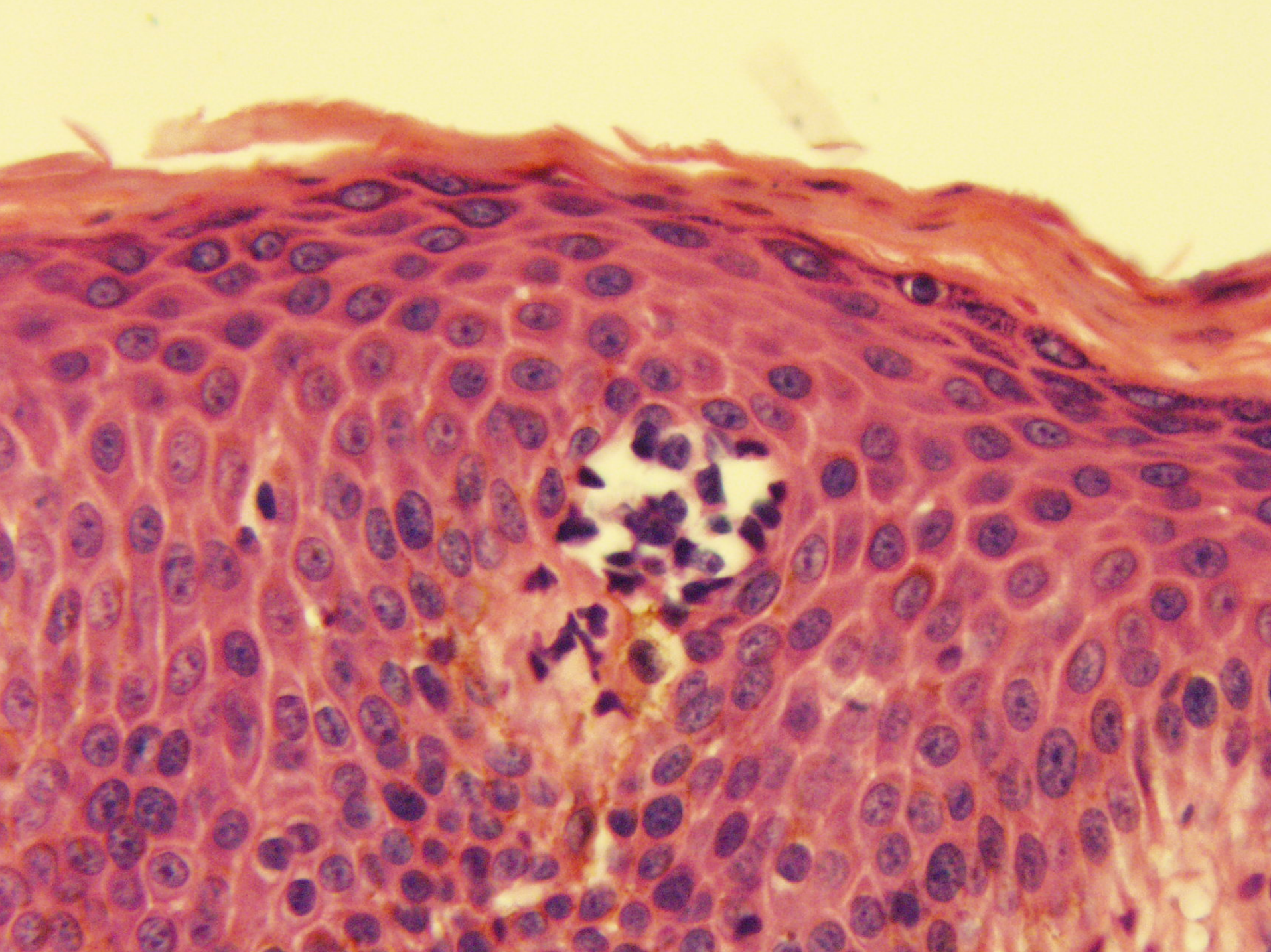















# **Mycosis Fungoides-Patch Stage**

Follicle



Scale

**Inflammatory Cell Type**

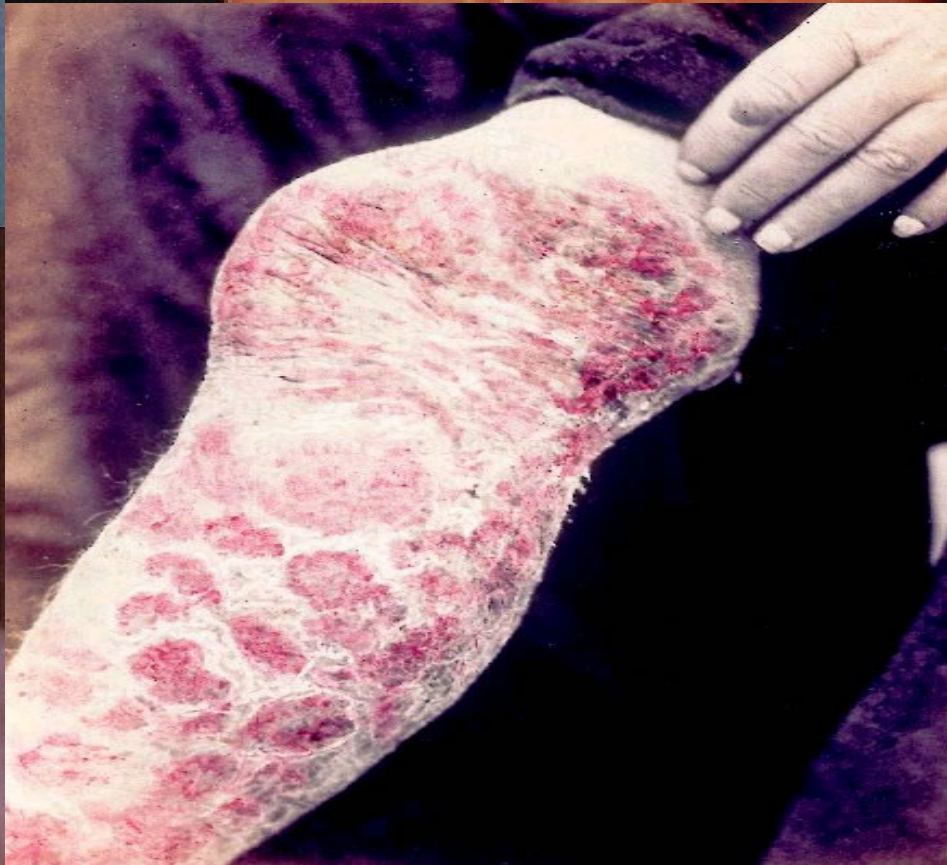
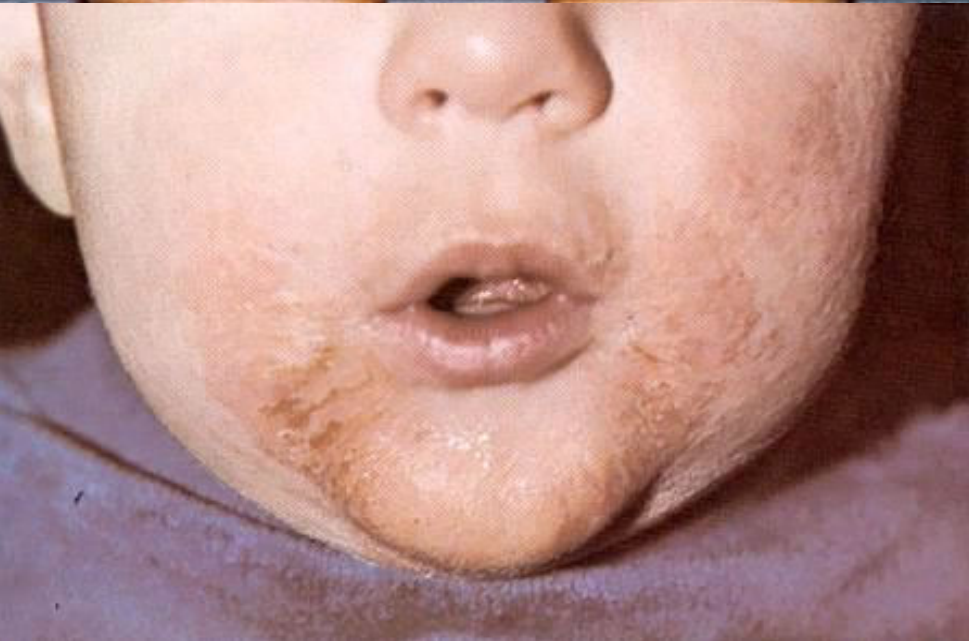
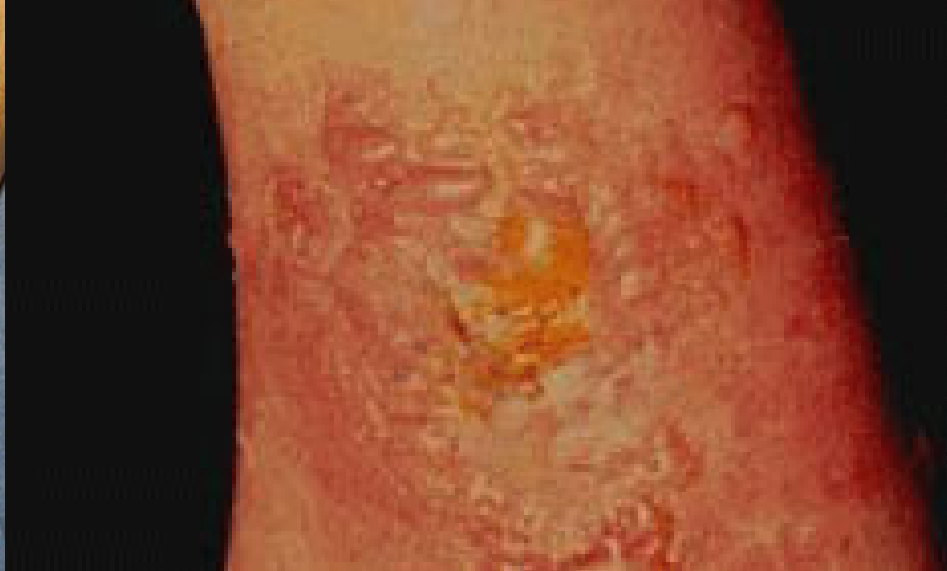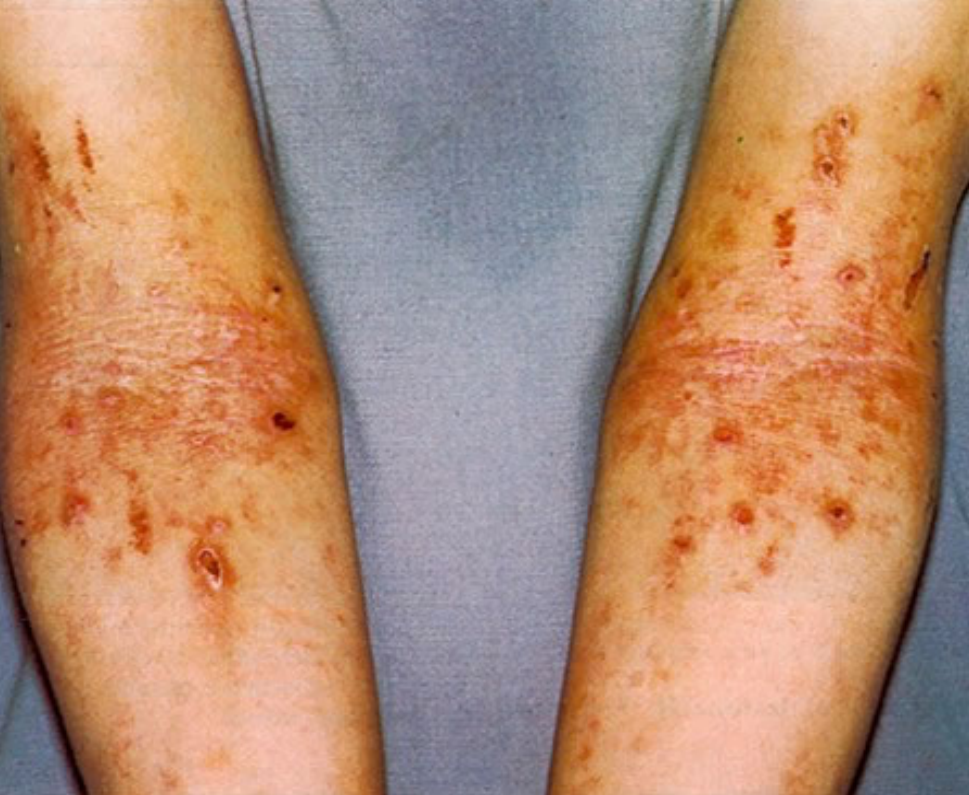# Focus


- Pautrier Microabscess
- Little spongiosis
- Basal intercalation of lymphocytes
- Cytologic atypia

**Spongiotic Dermatitis...**  
**We can be Specific!**





Follicle



Scale

Inflammatory Cell Type



I always wanted to be somebody, but  
I should have been more specific.

---Lily Tomlin