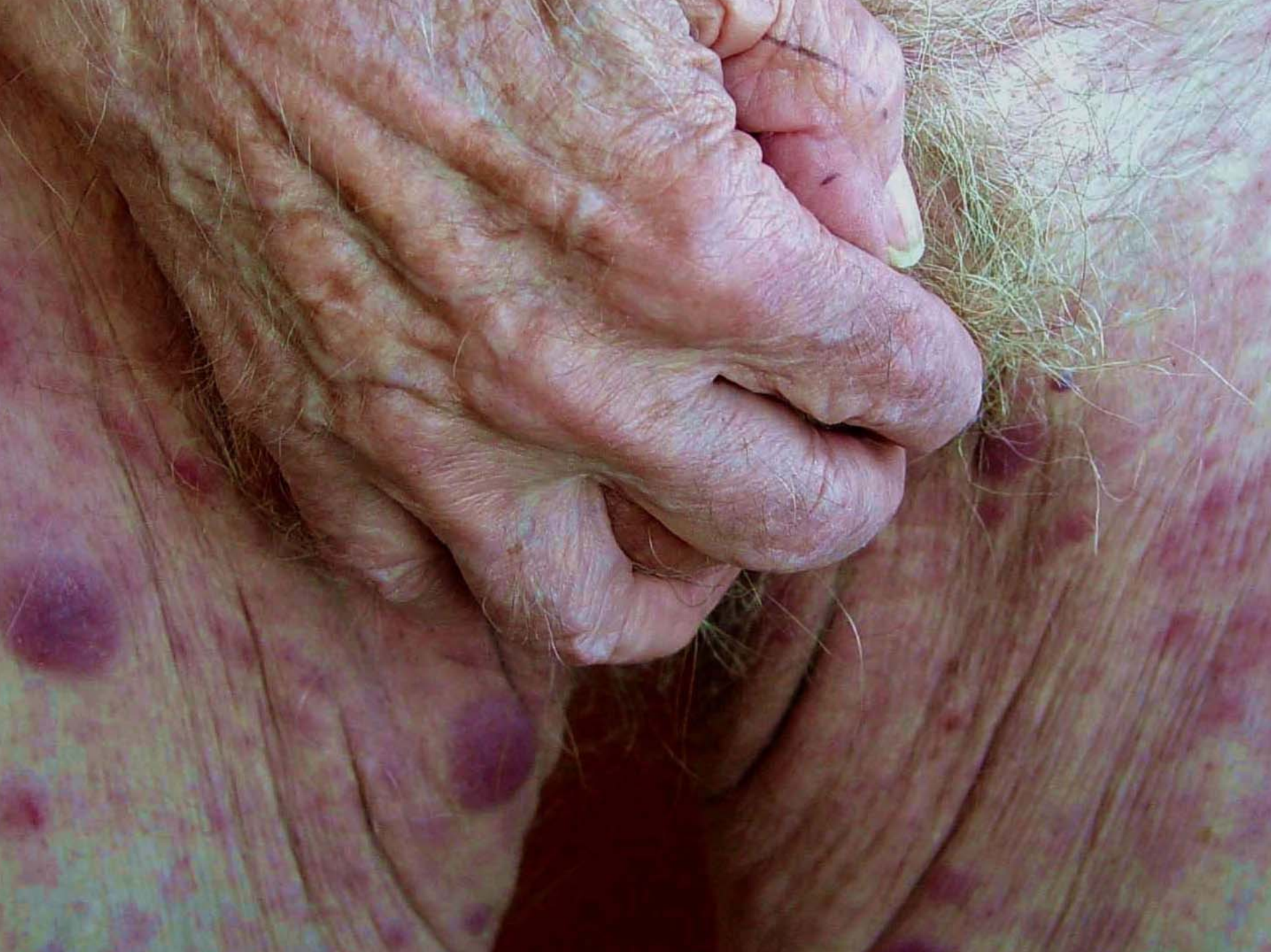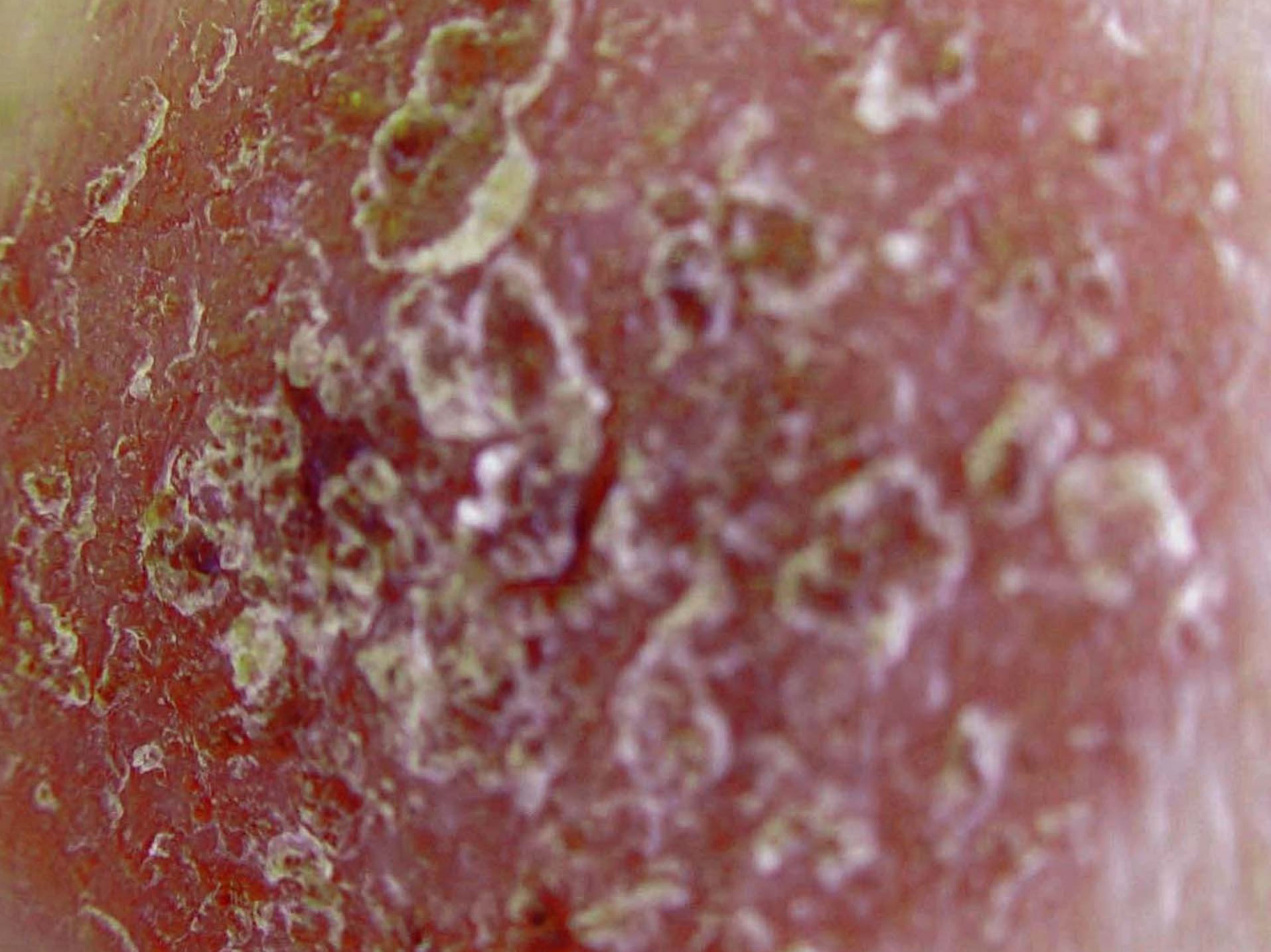


# Mycosis Fungoides- Can Pathologists Make the Diagnosis?

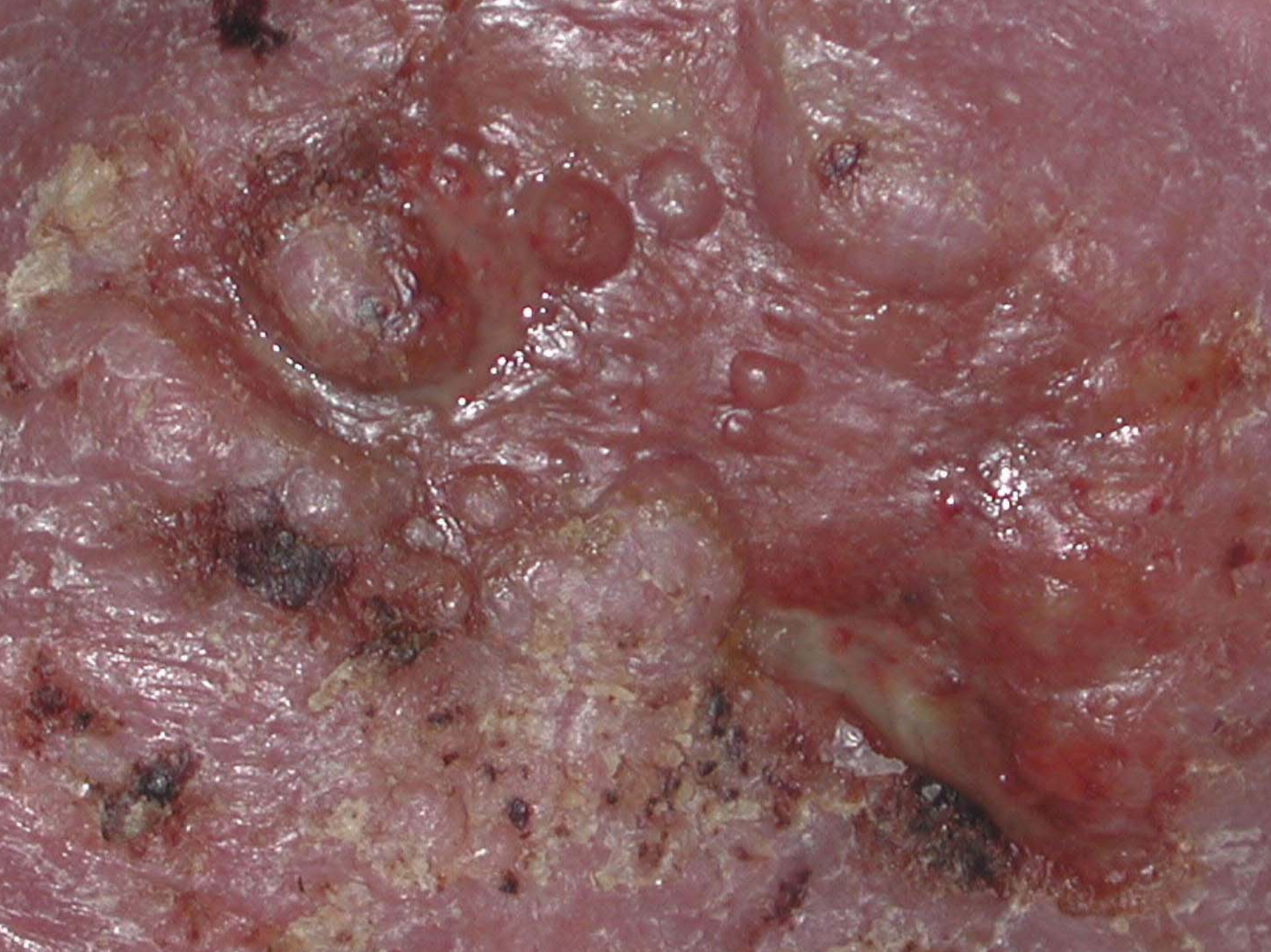
Paul K. Shitabata, M.D.  
Dermatopathologist  
APMG



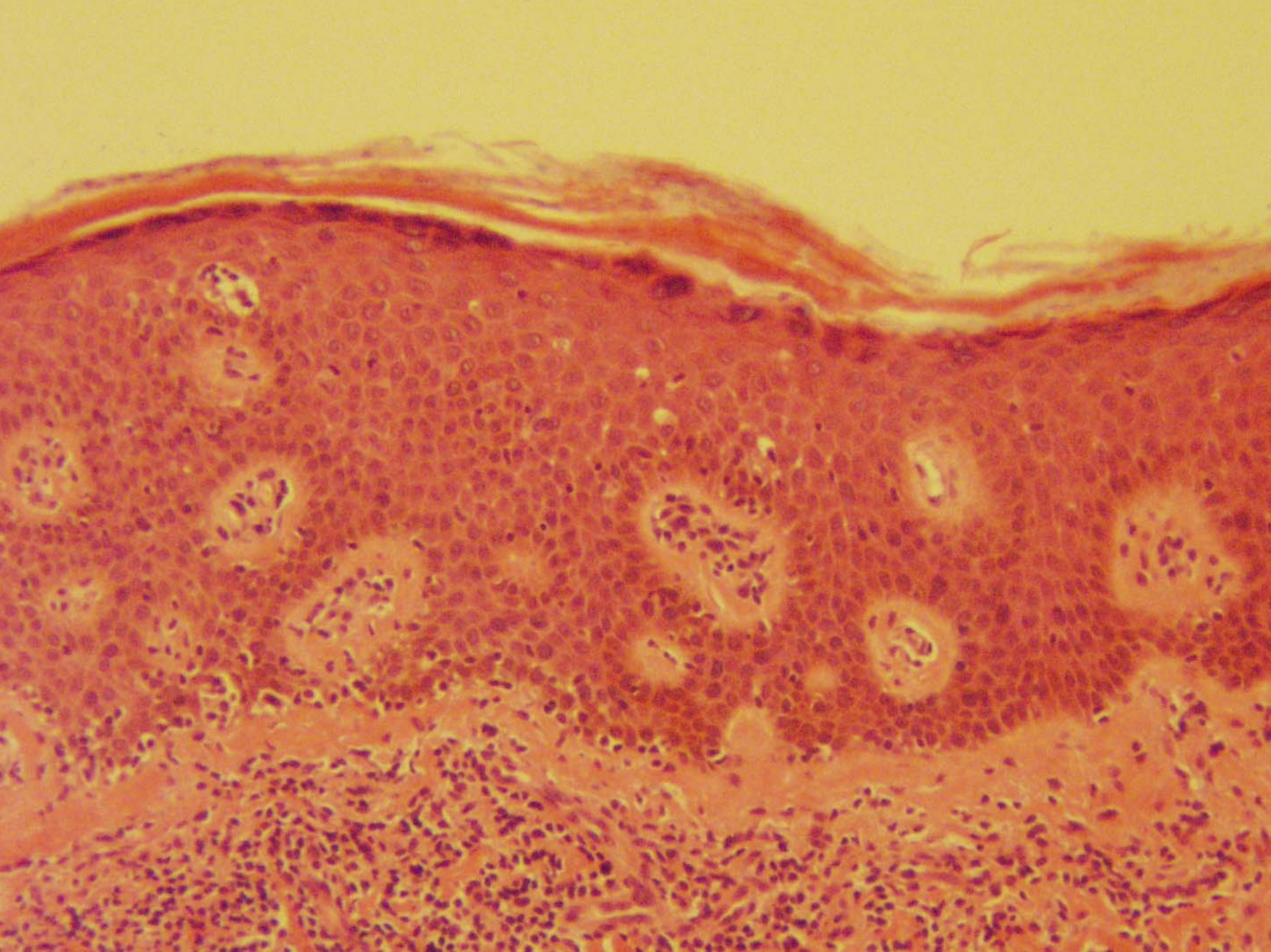




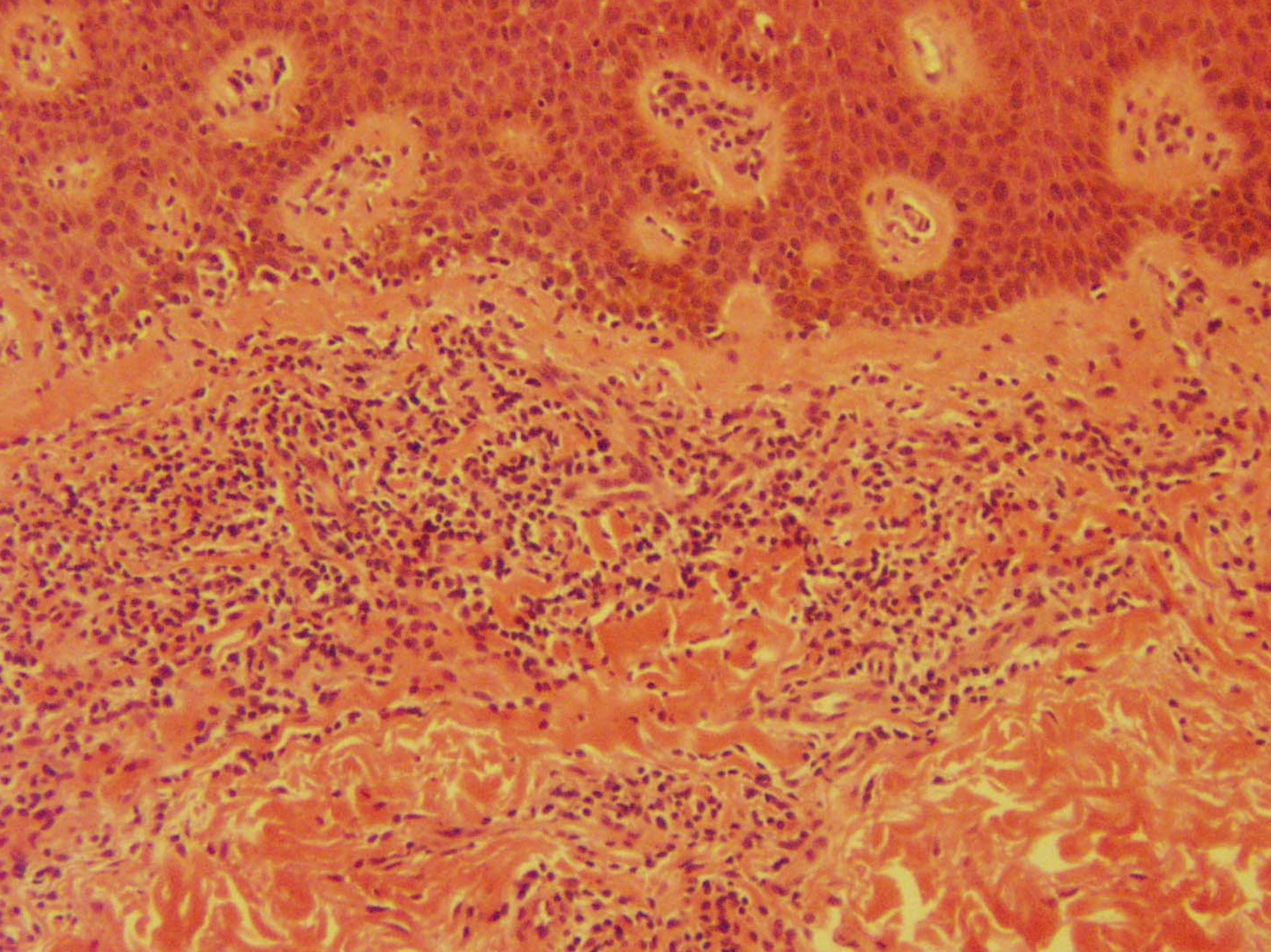




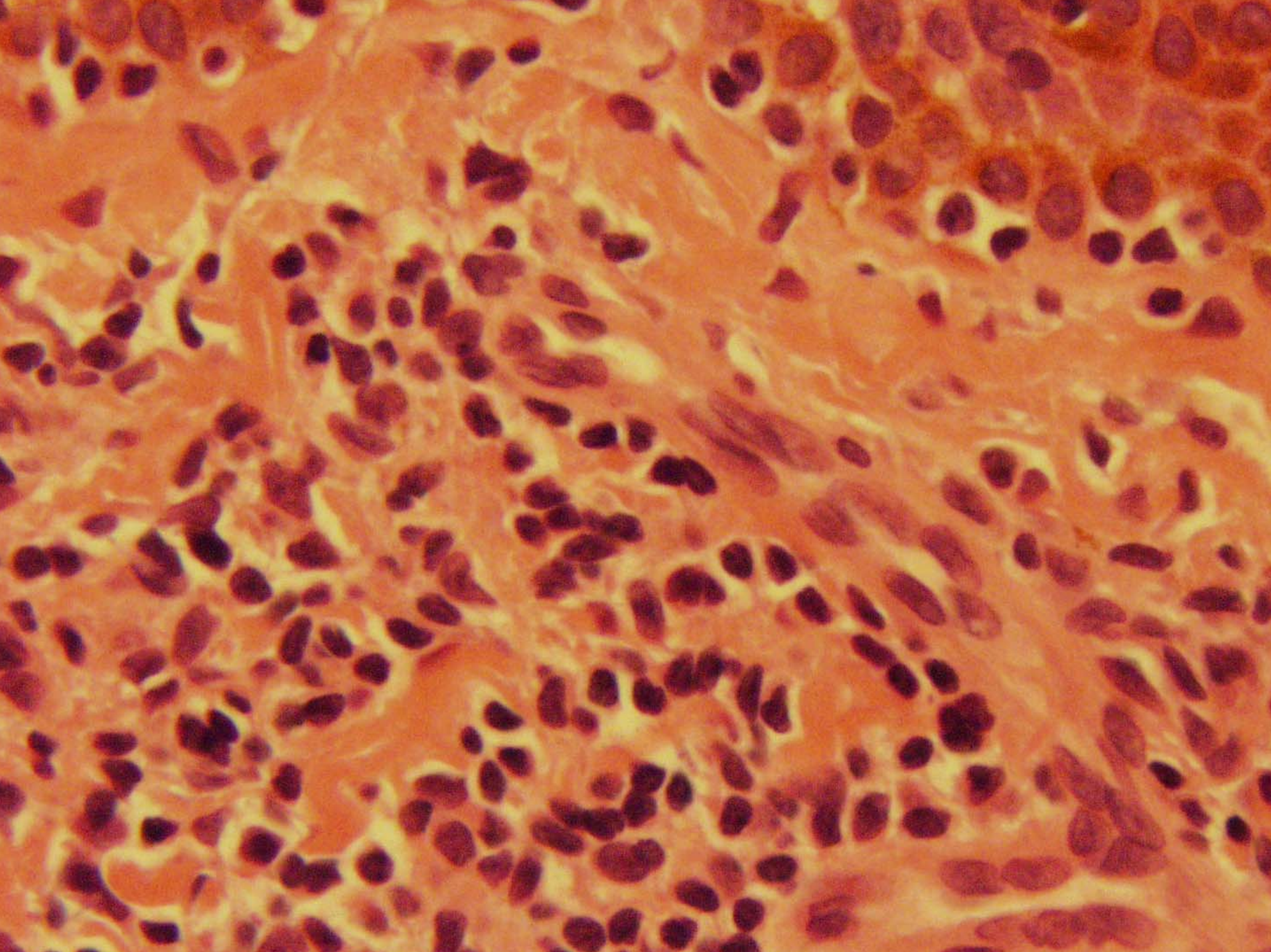




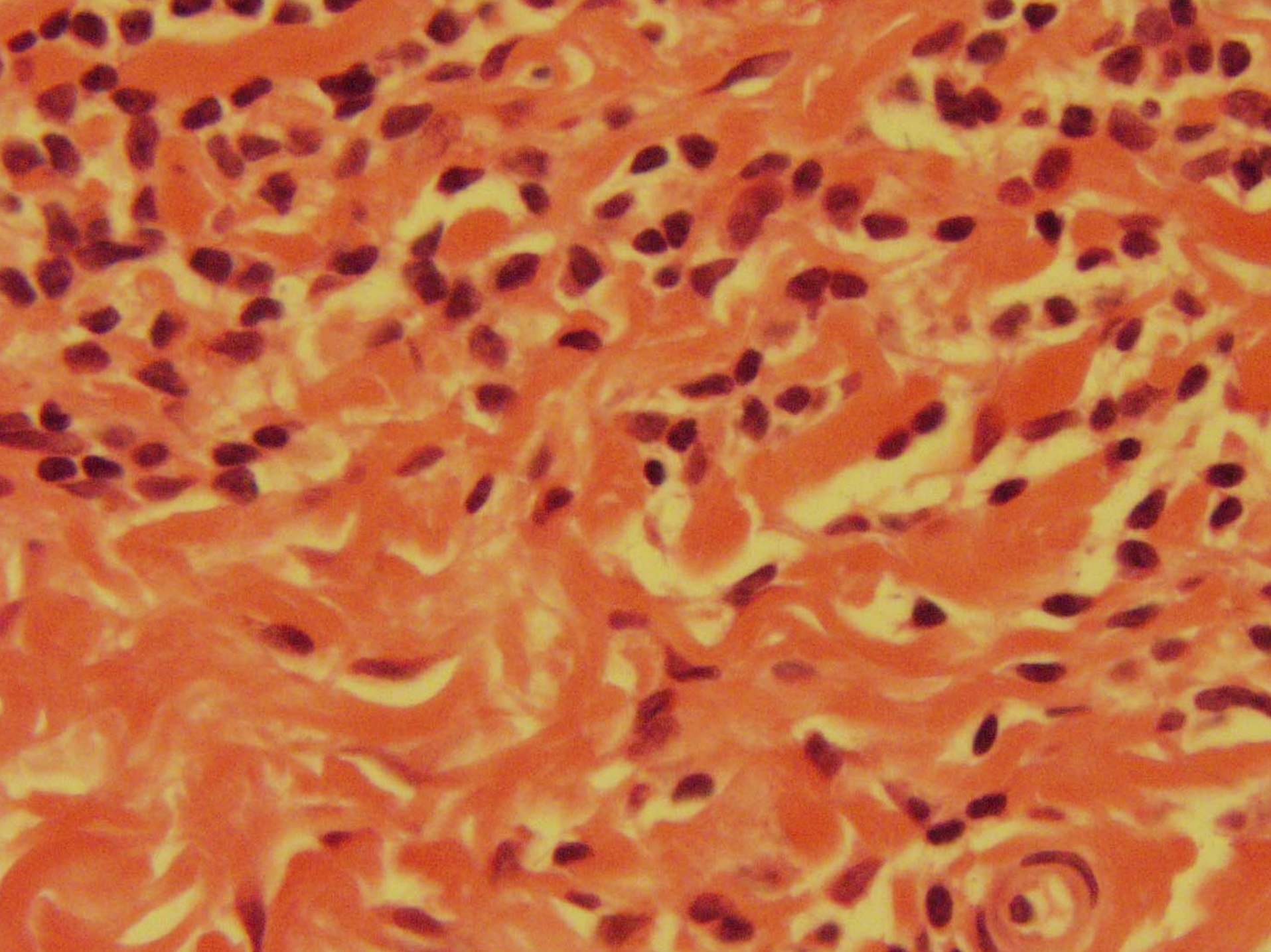














# Prevalence

TYPE	PERCENTAGE
Mycosis fungoides/SZ	82.3%
Lymphomatoid papulosis	12.6%
CD30+ anaplastic large-cell lymphoma	0.9%
Peripheral T-cell lymphomas	2.9%
B-cell lymphoma	4.5%



# EORTC Classification

Indolent	MF MF + follicular mucinosis Pagetoid reticulosis
CTCL-Large Cell CD30+	Anaplastic Immunoblastic Pleomorphic Lymphomatoid papulosis
CTCL-Aggressive	Sezary Syndrome Large cell, CD30 (-)Immunoblastic Large cell, CD30 (-)Pleomorphic
CTCL-Provisional	Granulomatous slack skin Pleomorphic small/medium sized Subcutaneous panniculitis-like T cell lymphoma



# Criteria

- Epitheliotropism with little spongiosis
- Lymphocytes lined up along the basal layer
- Hyperconvoluted lymphocytes
- Broad areas of slight hyperorthokeratosis that is compact or laminated, with subtle interspersed parakeratosis.
- Pautrier's microabscesses
- Granulomatous foci
- Coexistence of plasma cells and eosinophils
- Rounded, hyperplastic rete ridges adjacent to flattened rete
- Wiry collagen dissected by atypical lymphocytes



# And the Winner Is...

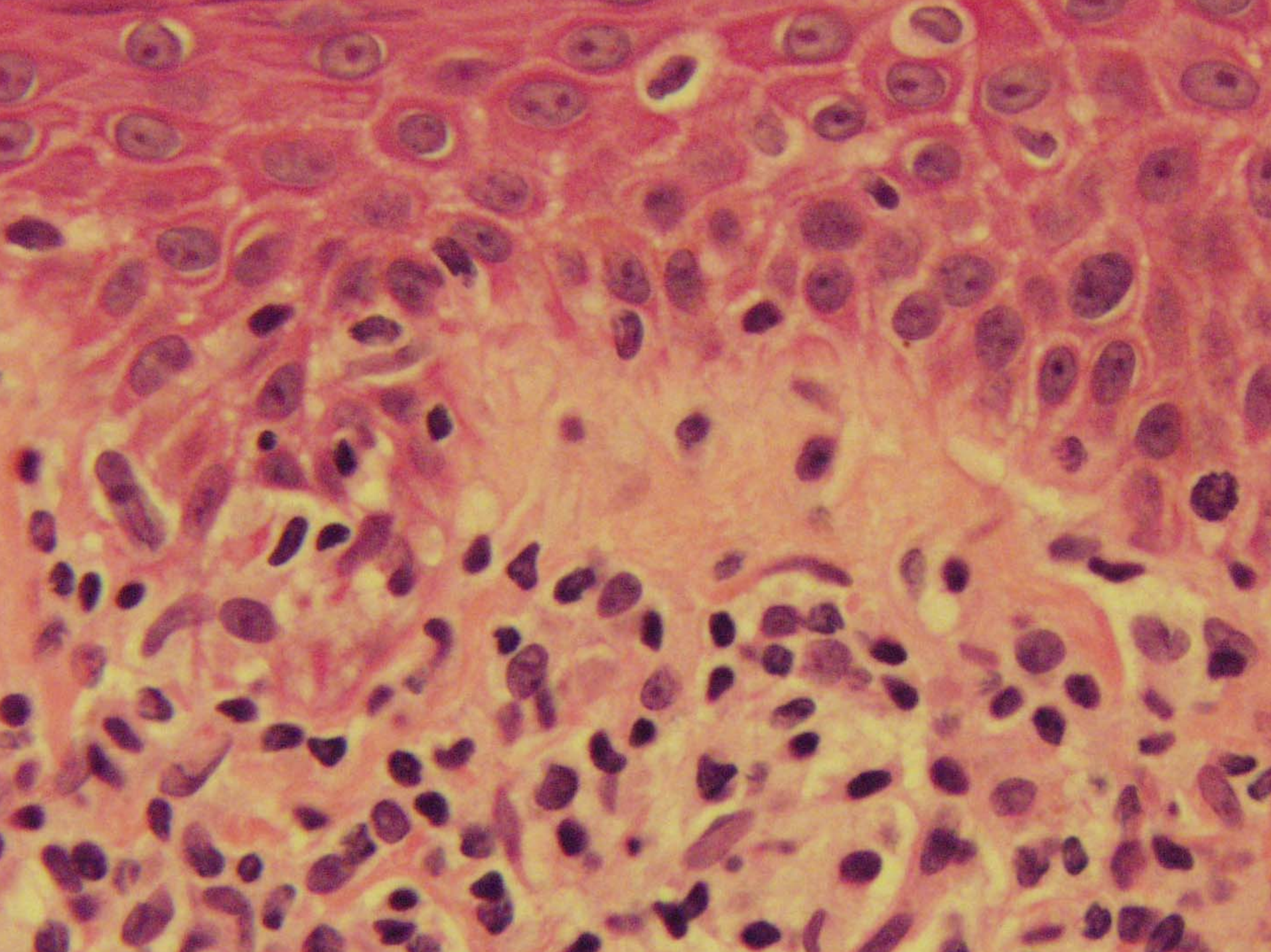
- Larger Intraepidermal Lymphocytes
- Pautrier microabscesses
- Basilar Epidermotropism
- Haloed lymphocytes



# Larger Intraepithelial Lymphocytes

- Lymphocytes within the epidermis which are larger than those within the dermis in approximately 20% of examples
  - Early MF, few neoplastic cells may be present in any given biopsy and in reality, the histologic features that are assessed are probably a reaction pattern to tumor



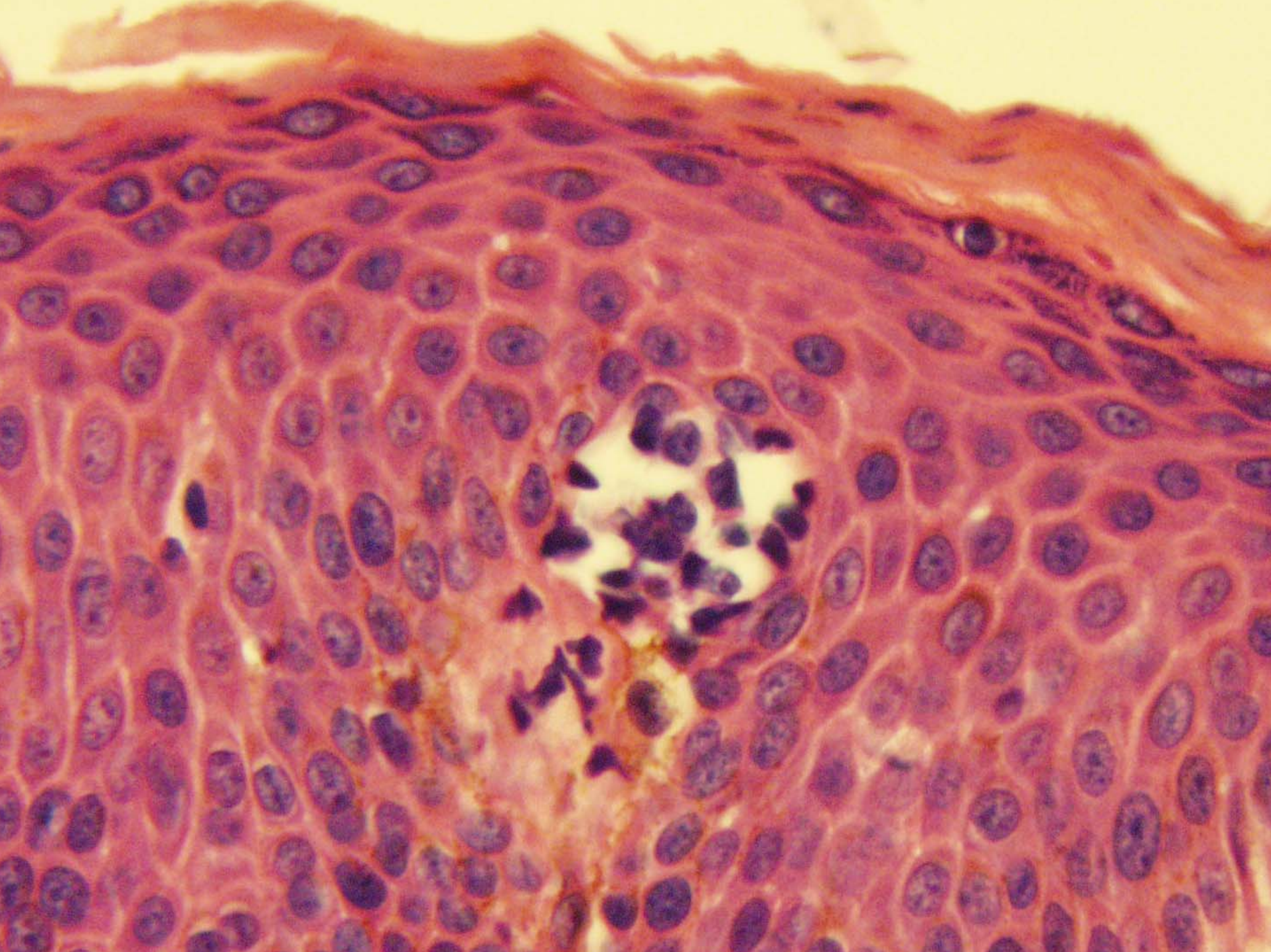




# Pautrier Microabscesses

- Pautrier's microabscesses are found in 4 to 37% of cases
- Rule out Pseudo-Pautrier microabscesses

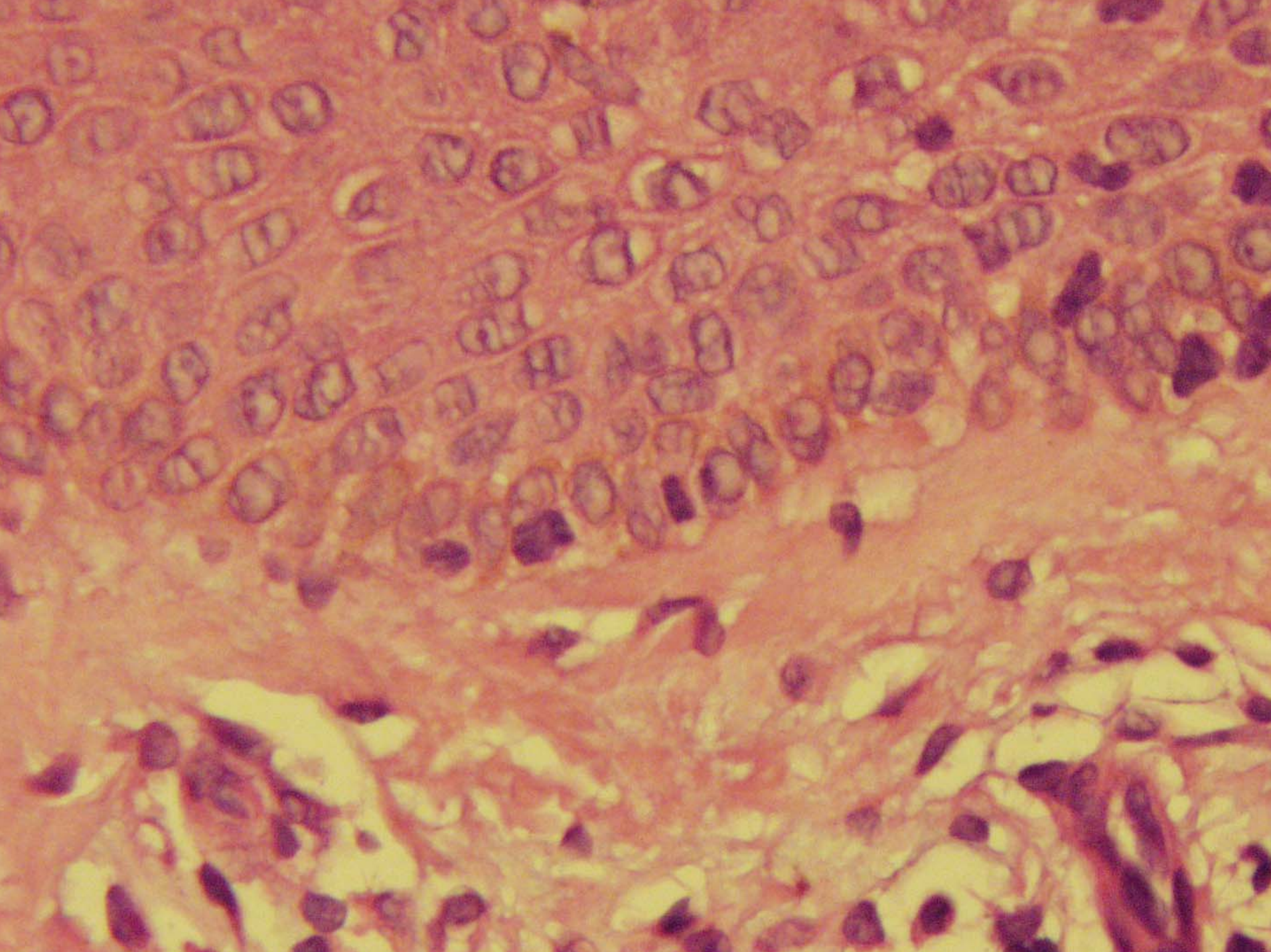




# Basilar Epidermotropism

- Epidermotropism associated with a paucity of spongiosis (disproportionate epidermotropism) may be found in approximately 58% of MF cases and approximately one quarter of controls.
- Basilar epidermotropism (“a string of pearls” or “toy soldiers”) when it is defined as one to five basal lymphocytes per 20×field, was identified in more than two thirds of MF cases and fewer than a quarter of controls in one study
  - One study defined it as the presence of any four contiguous lymphocytes within the basal layer finding this be a specific but insensitive feature (93% specificity, 17% sensitivity for early MF).
  - Pagetoid spread, especially lymphocytes high in the epidermis may be more significant than basilar lymphocytes in some differentials.



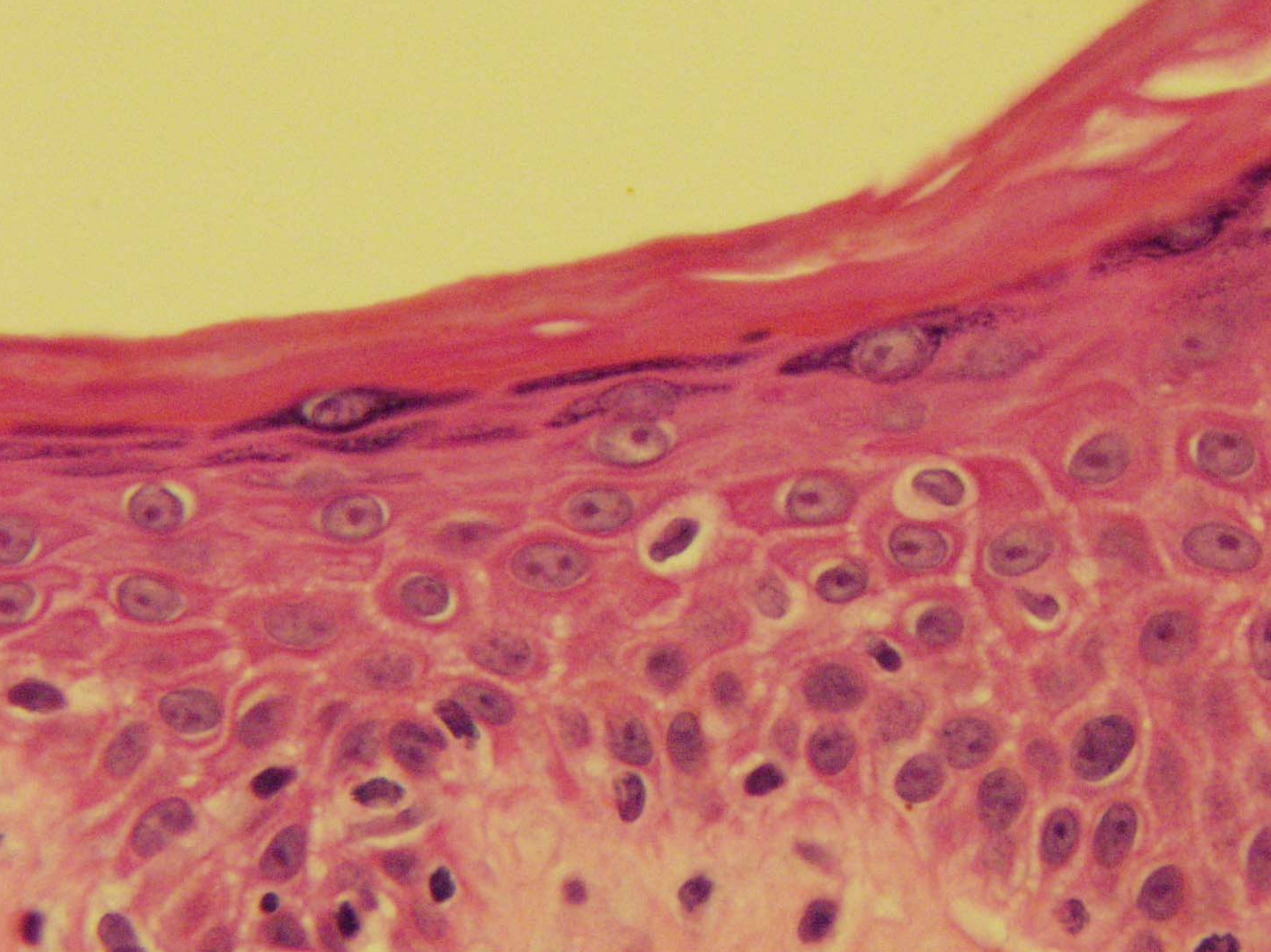


# Haloed Lymphocytes

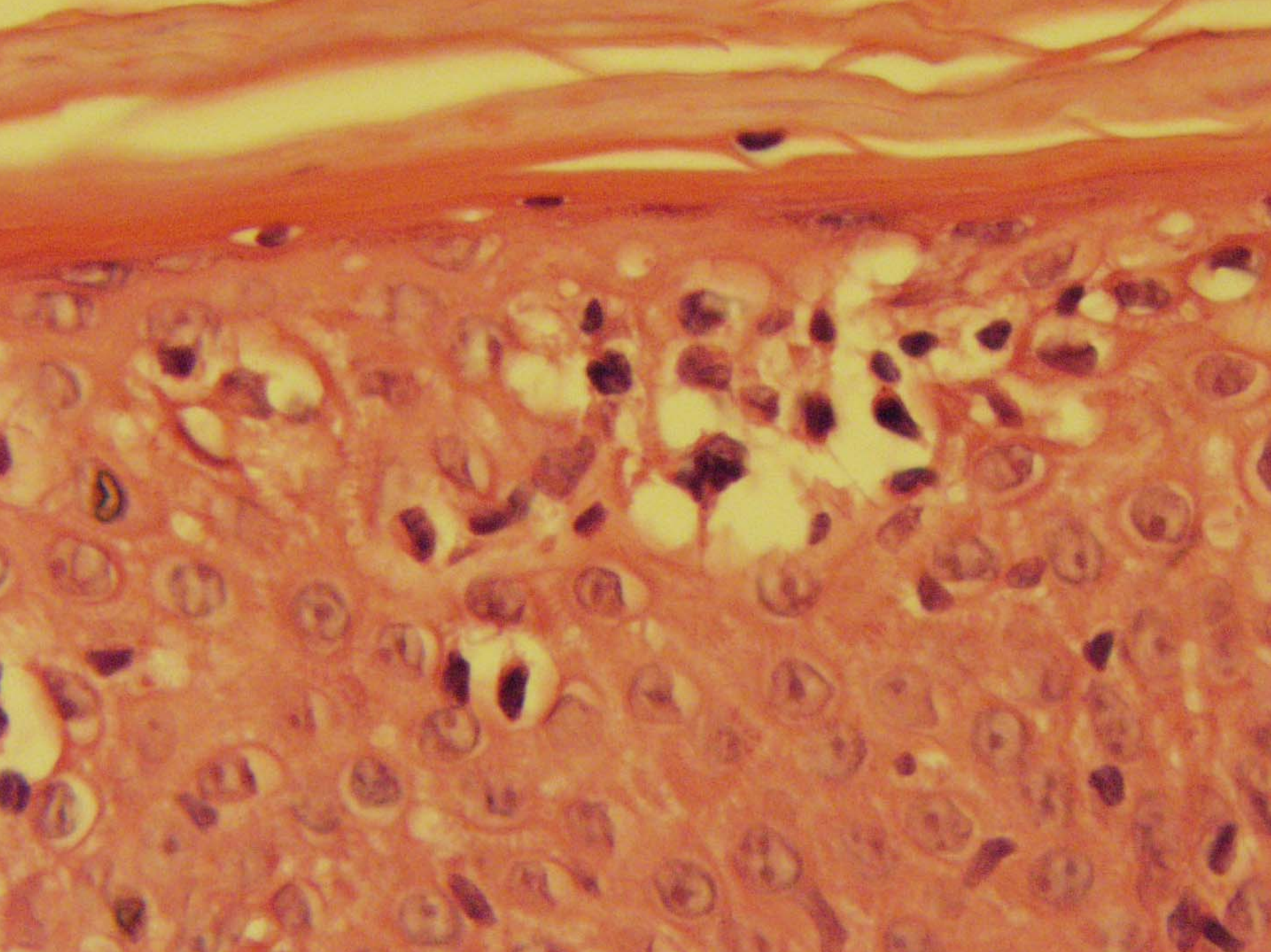
- Thought to result from artifactual contraction of the more abundant cytoplasm of neoplastic lymphocytes and are not typically identified in frozen sections
- Best evaluated for in the upper epidermis rather than within the basal layer, where they may be confused with melanocytes.
- Lymphocytes with a halo identifiable even at low magnification of "moderate degree" (1–5 per 20×field) in 59% of MF samples and 13% of patients biopsied to rule out MF who ultimately proved to have an inflammatory condition
- Haloed lymphocytes were the best single discriminator of MF from inflammatory simulants

- Am J Surg Pathol 1995; 19: 1423.  
Am J Dermatopathol 1979; 1: 5





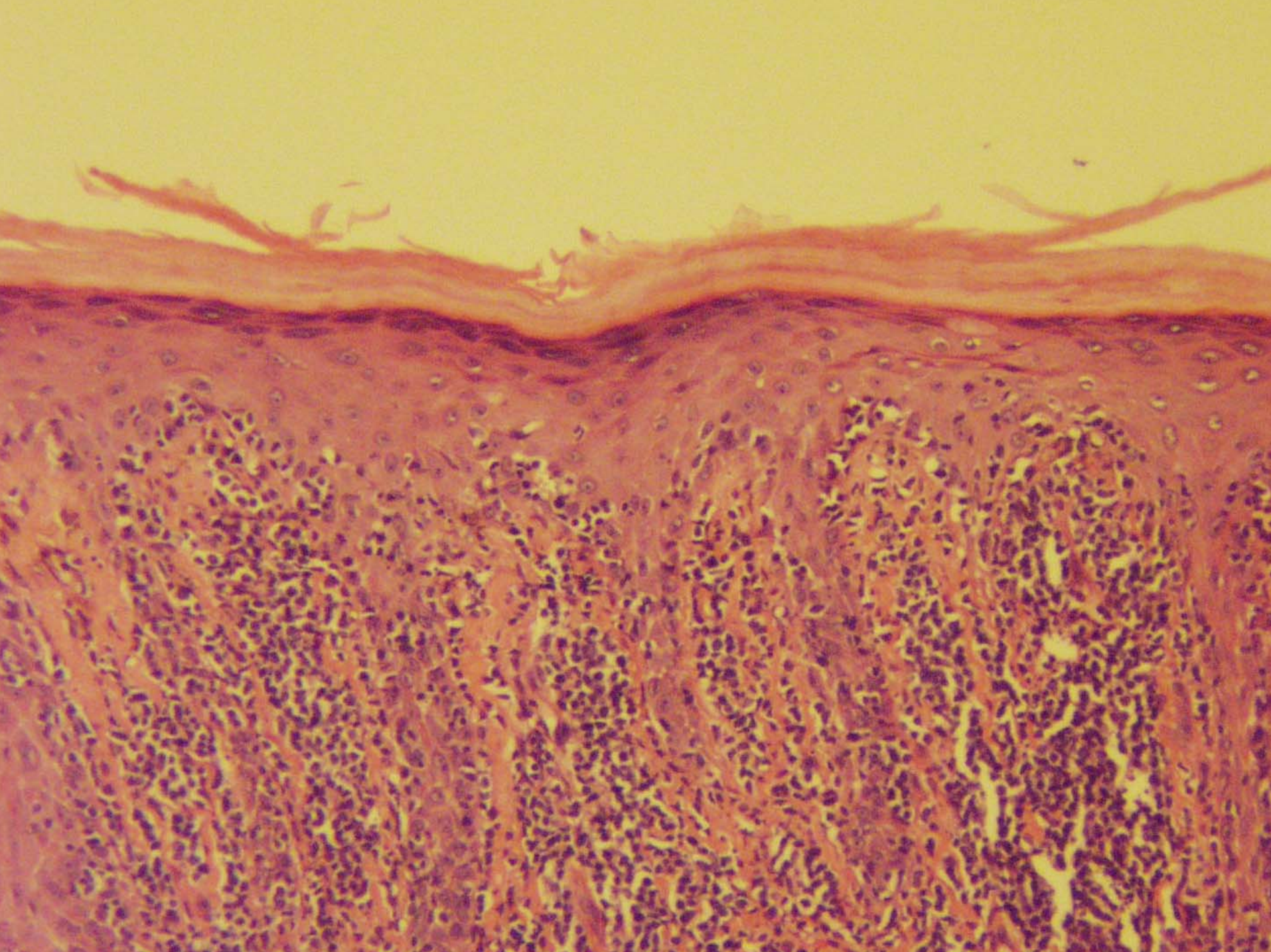




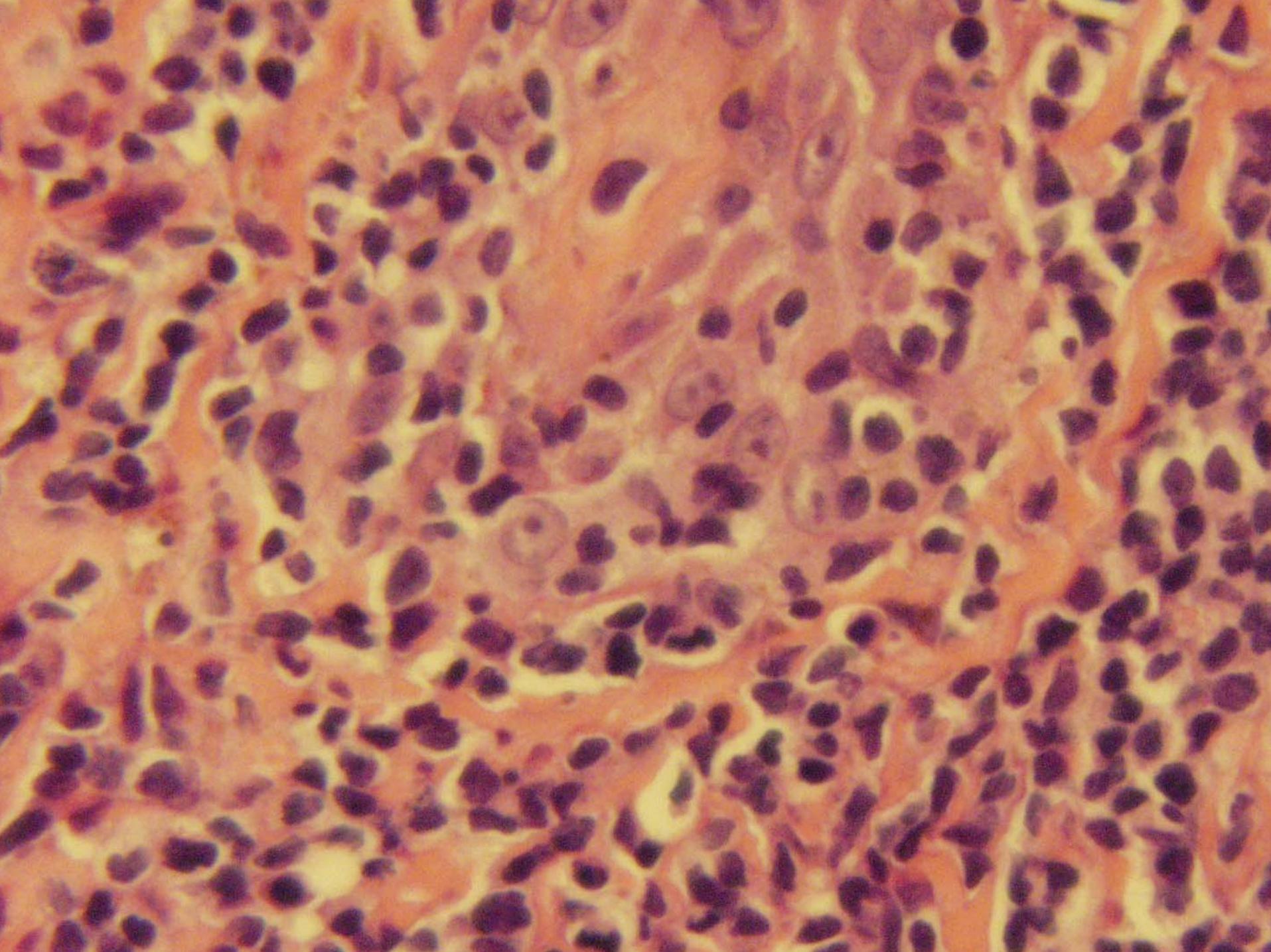


# Stages

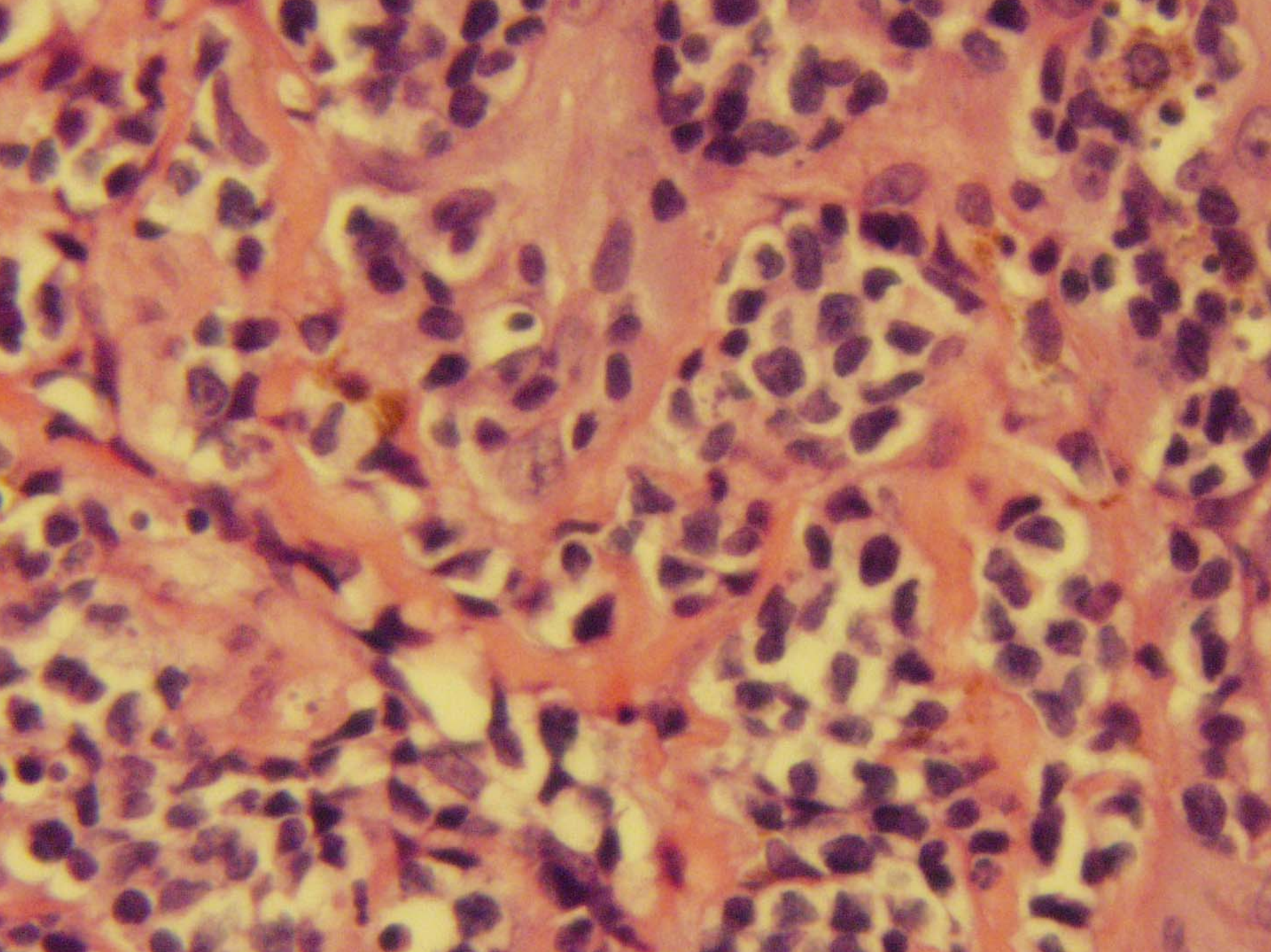
- Patch
- Plaque
- Tumor
  - Tumor D'emblee



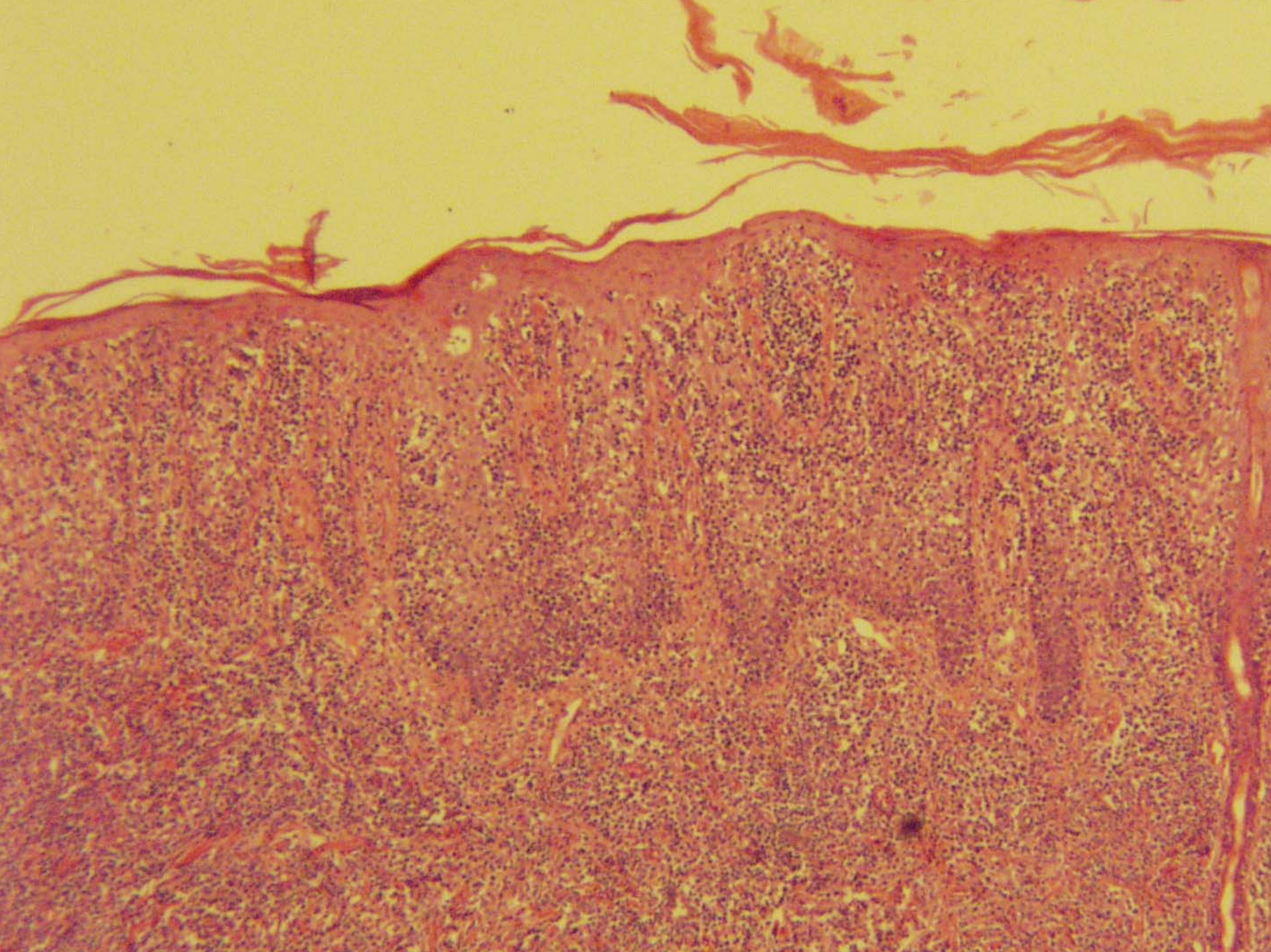




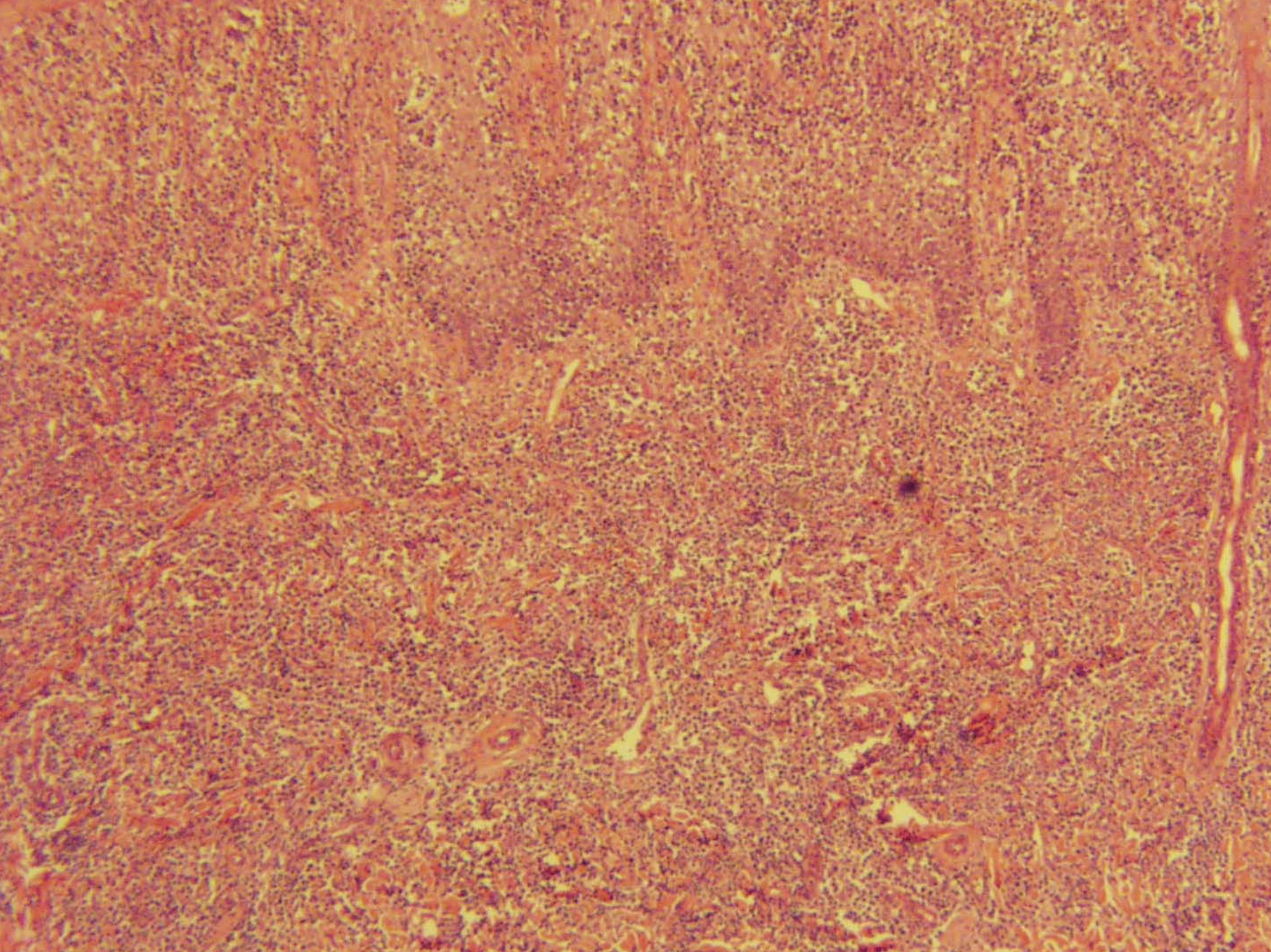












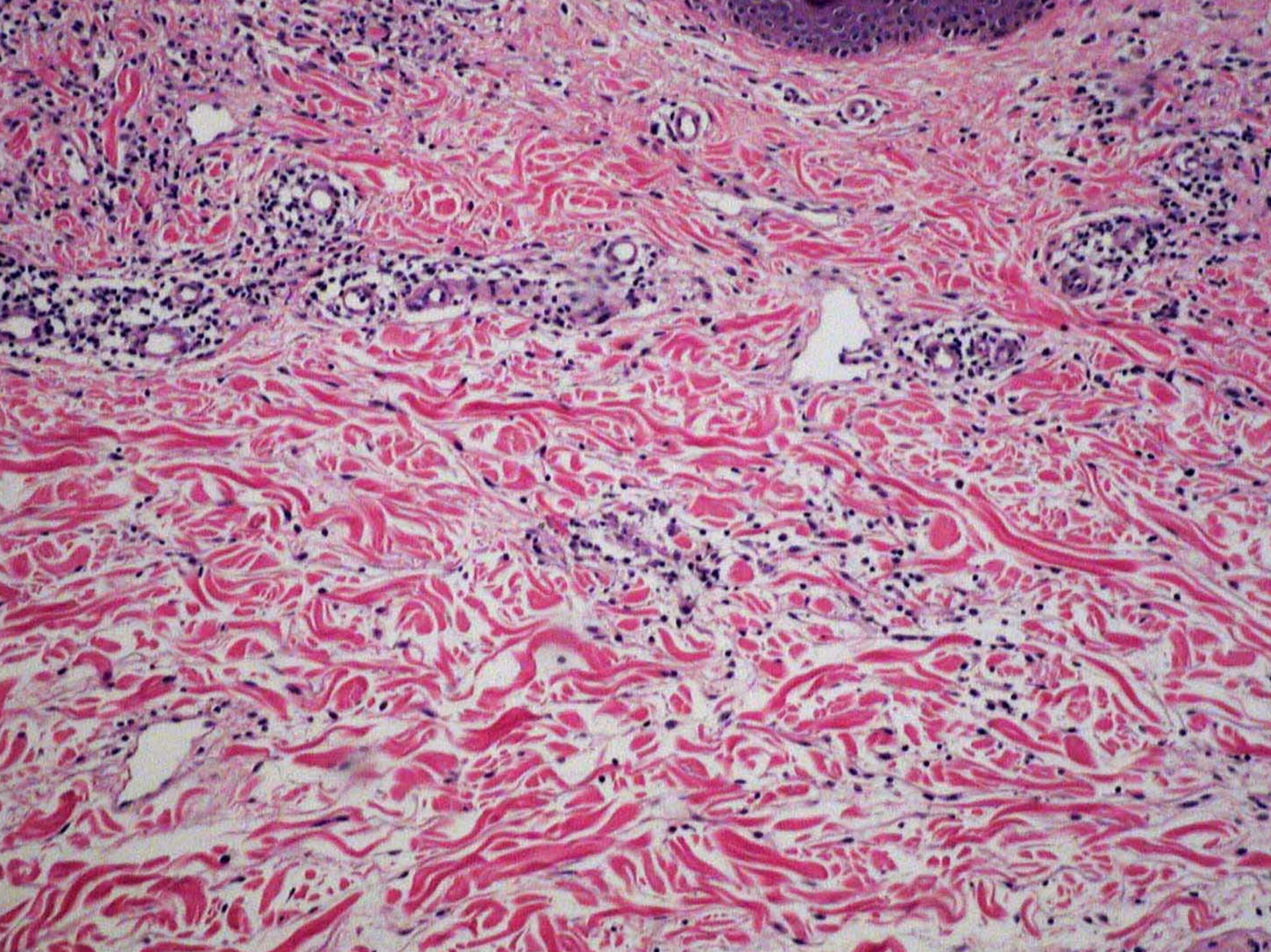


# Beware the Variants

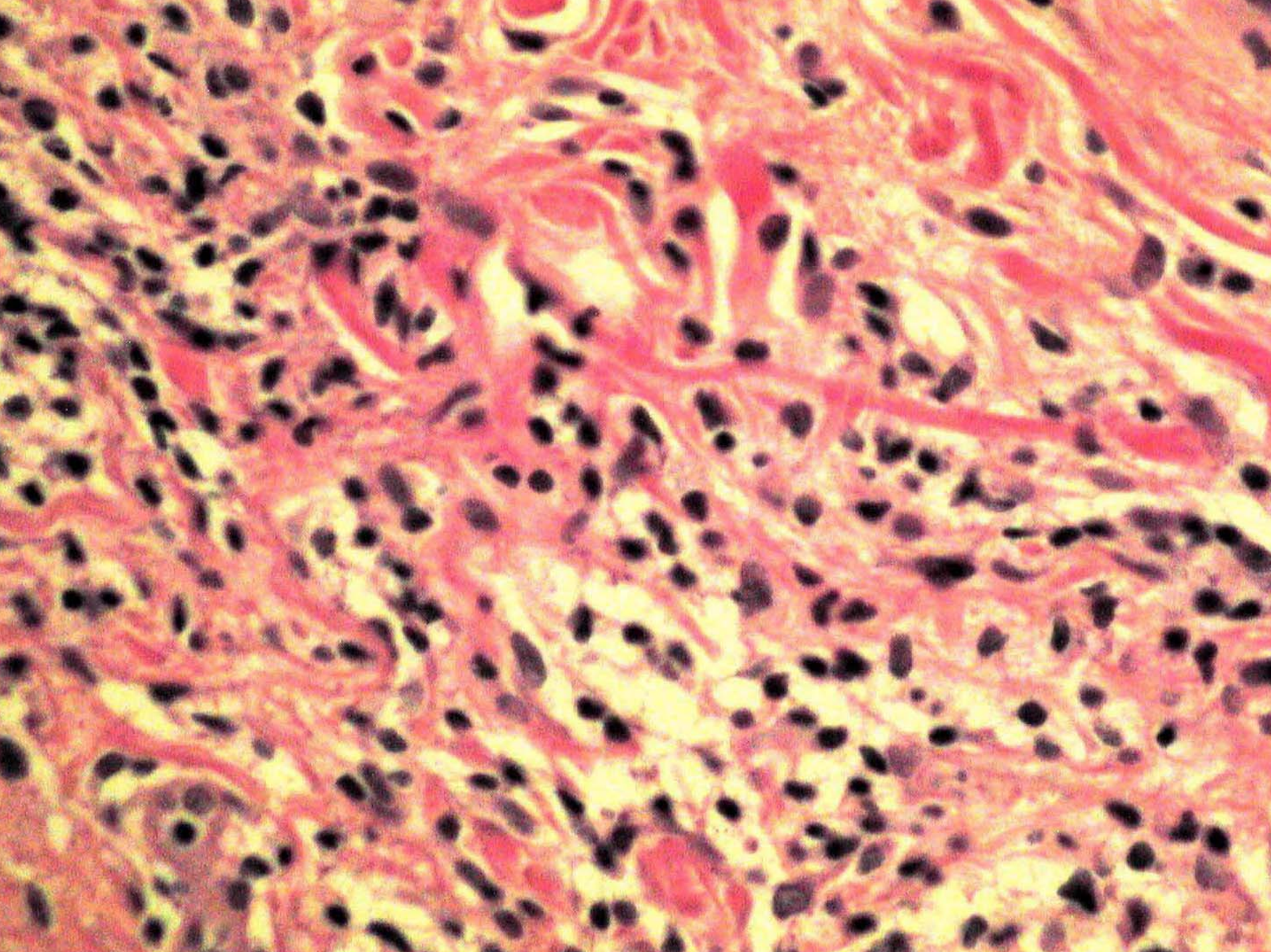
- Lack of epidermal involvement
- Granulomas
- Mucinous
- Follicular
- Pigmented purpura-like
- Syringotropic
- Clinical
  - Hypopigmented
  - Unilesional









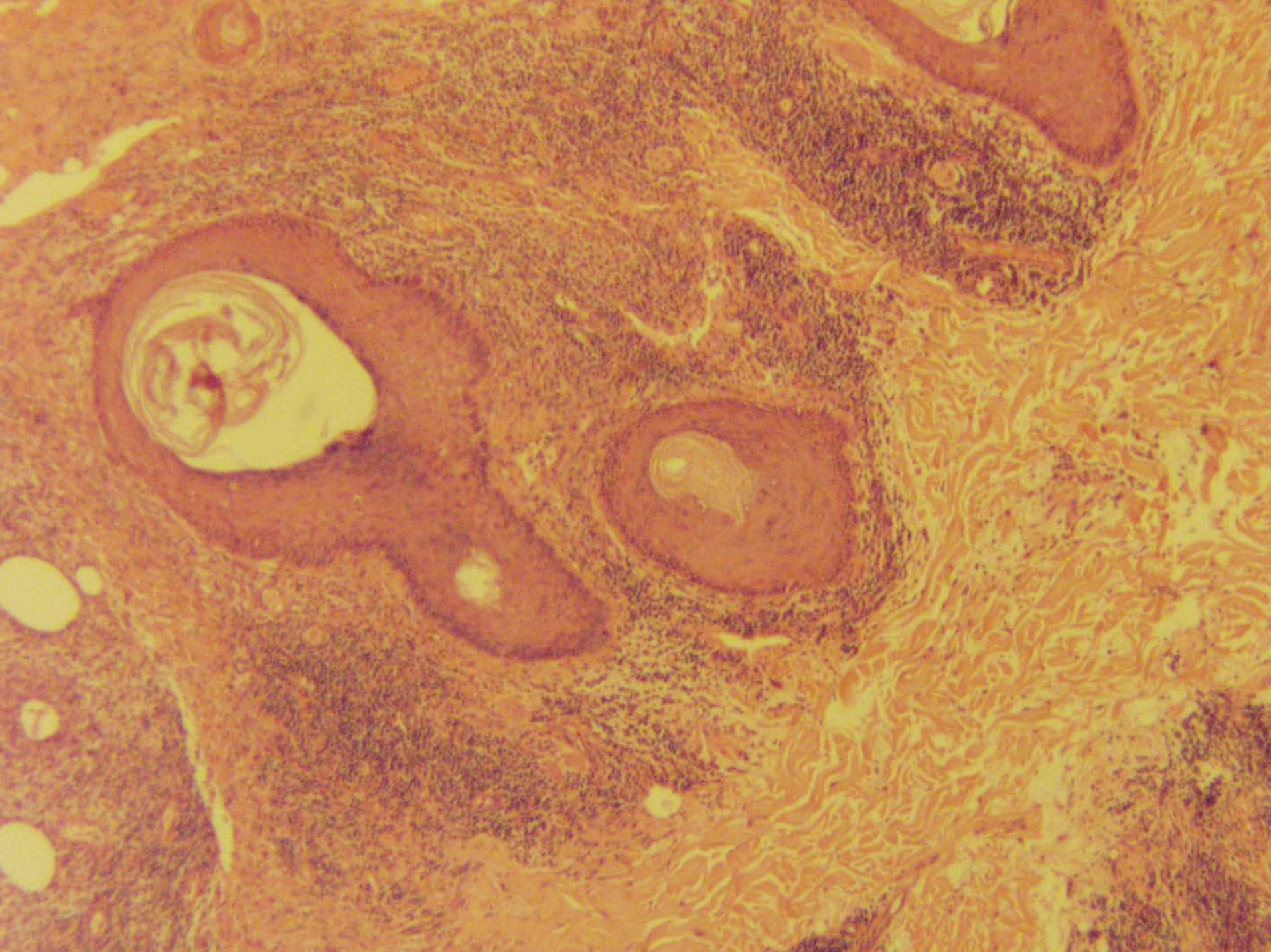




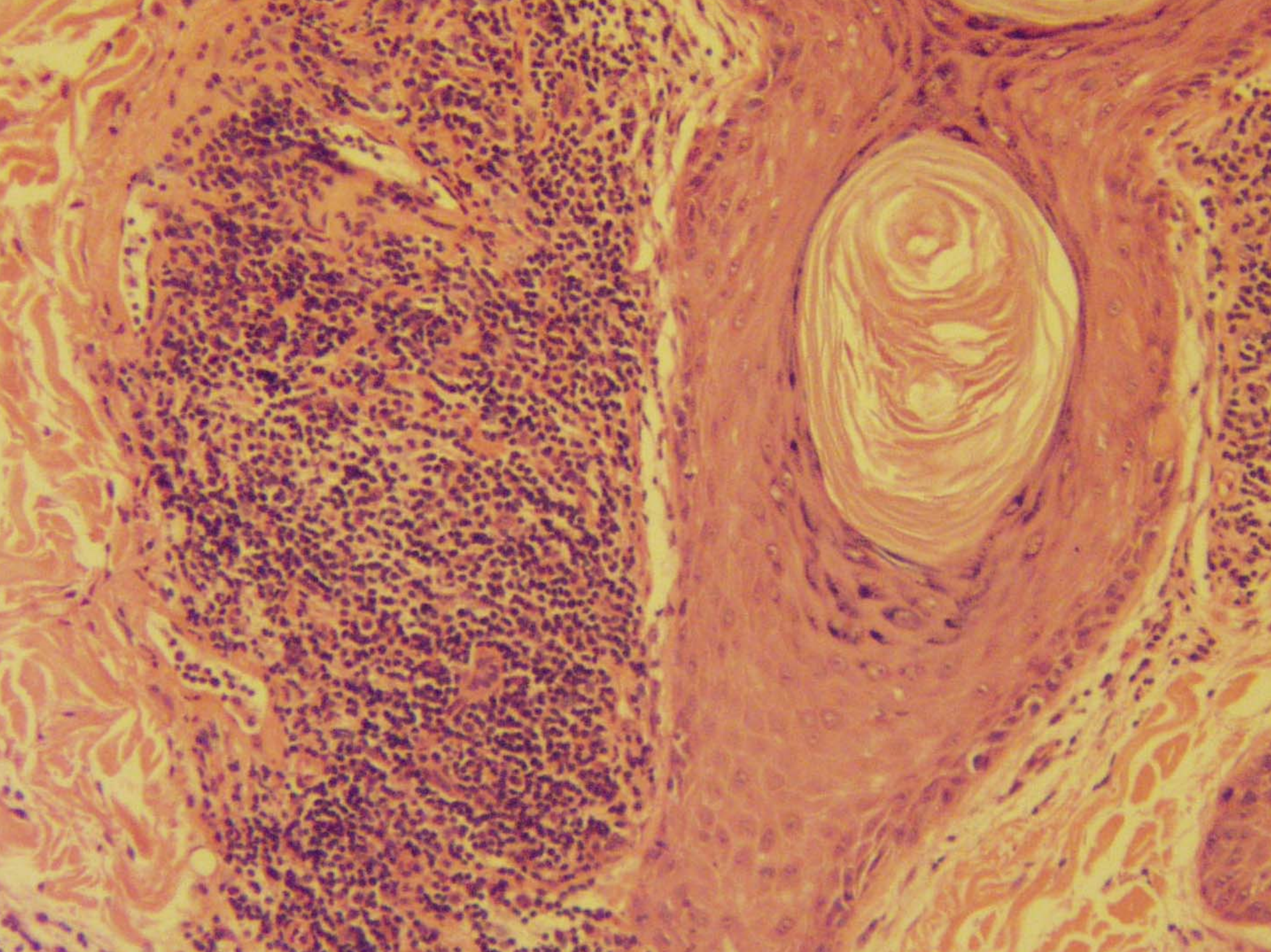
# Interstitial Variant

- Non-indurated, erythematous macules; ill-defined erythematous plaques with slight scale; and nodules on the trunk and proximal limbs
- Striking dermal interstitial infiltrate of lymphocytes with rare histiocytes that resembled the interstitial form of granuloma annulare or inflammatory morphea
  - Epidermotropic lymphocytes were present at least focally in all cases
  - A band-like lymphocytic infiltrate was observed in two of five cases. In contrast, many plasma cells and
  - Increased dermal mucin deposition was observed in 2/5
- Dominant population of T cells (CD3+) in the dermis and epidermis.
  - Clonal T-cell population was detected by PCR T-cell gamma gene rearrangement analysis (2/5)
- Mycosis fungoides occasionally presents as an interstitial lymphocytic infiltrate that mimics granuloma annulare and inflammatory morphea.

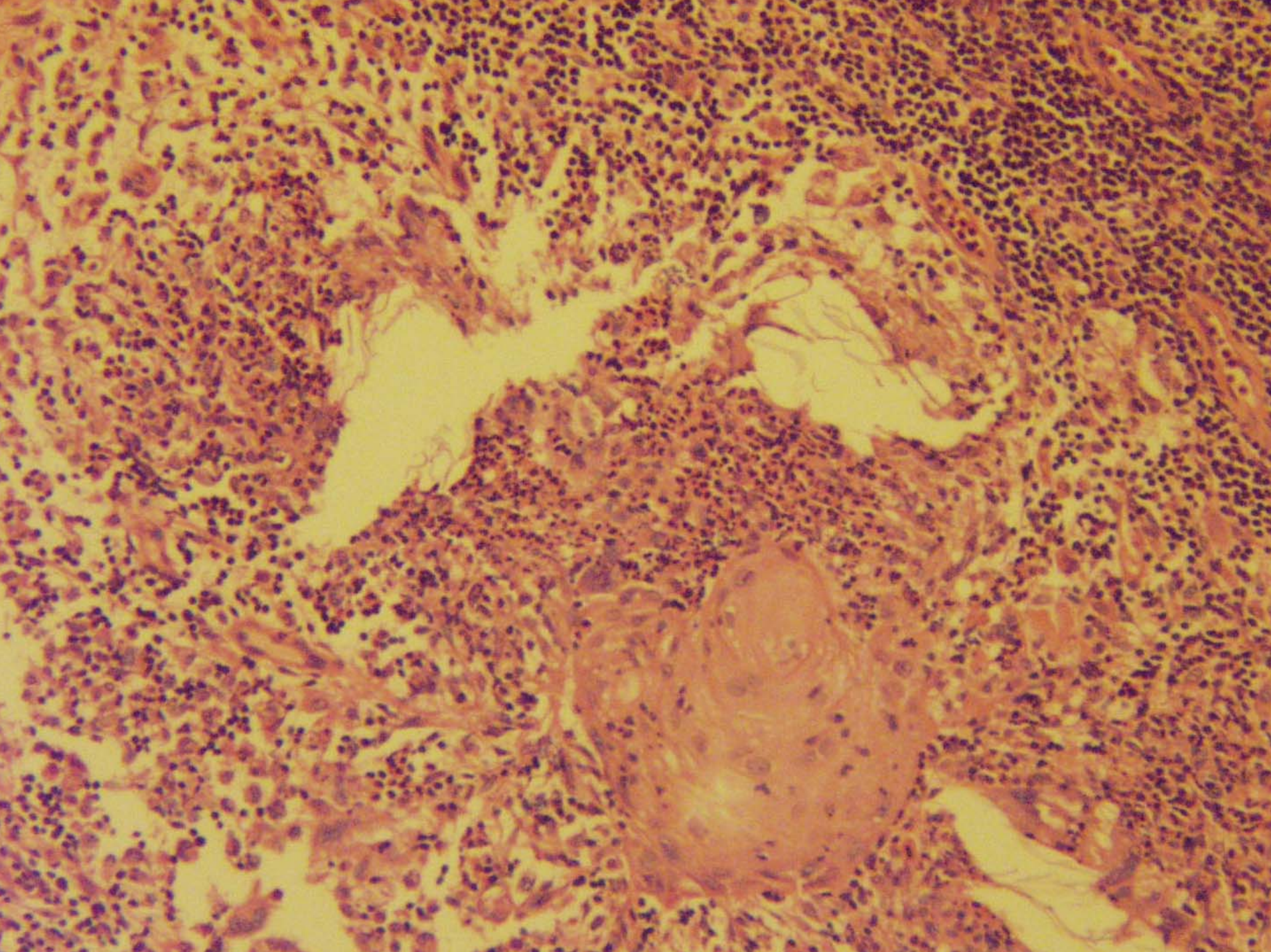




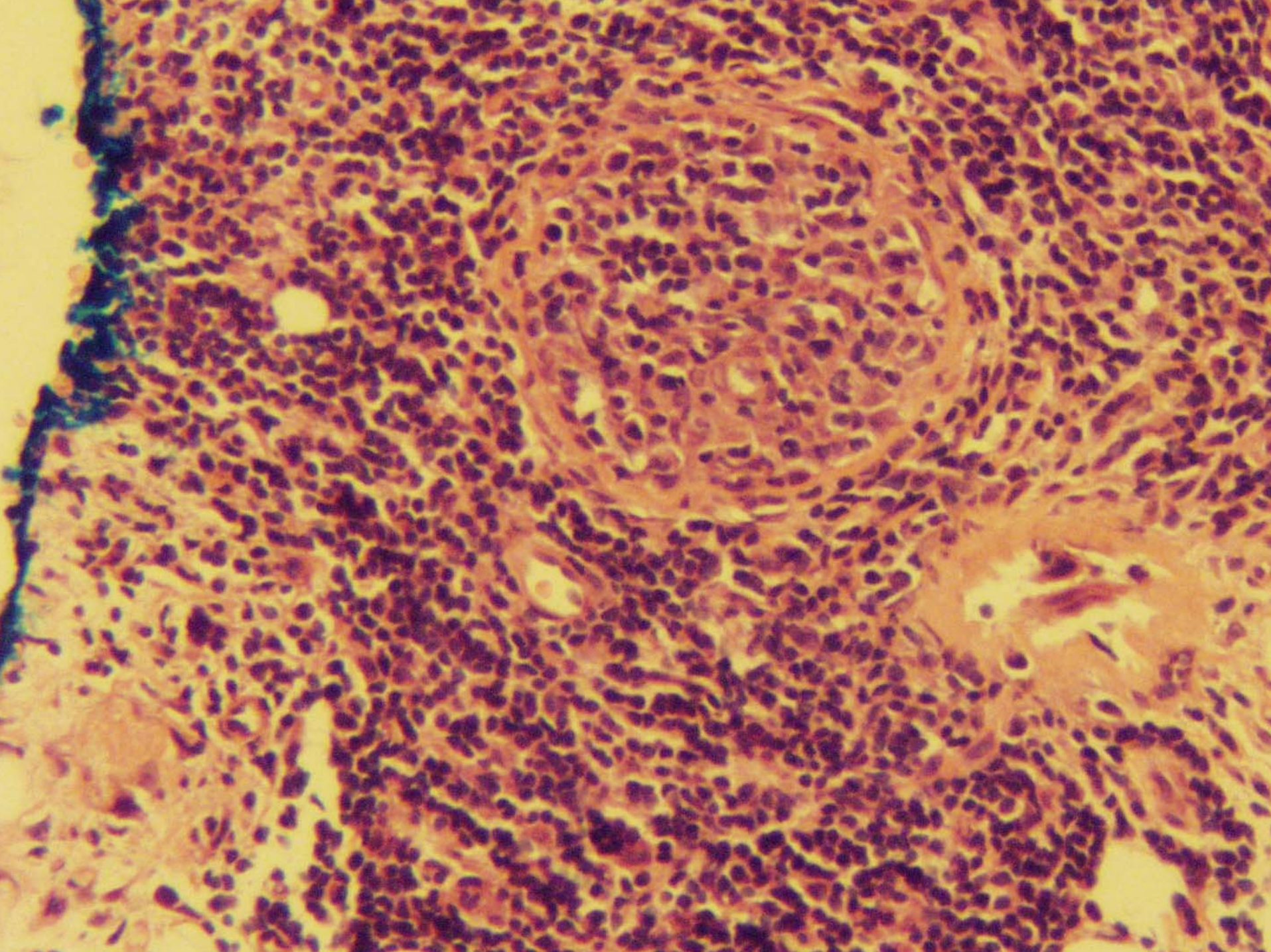




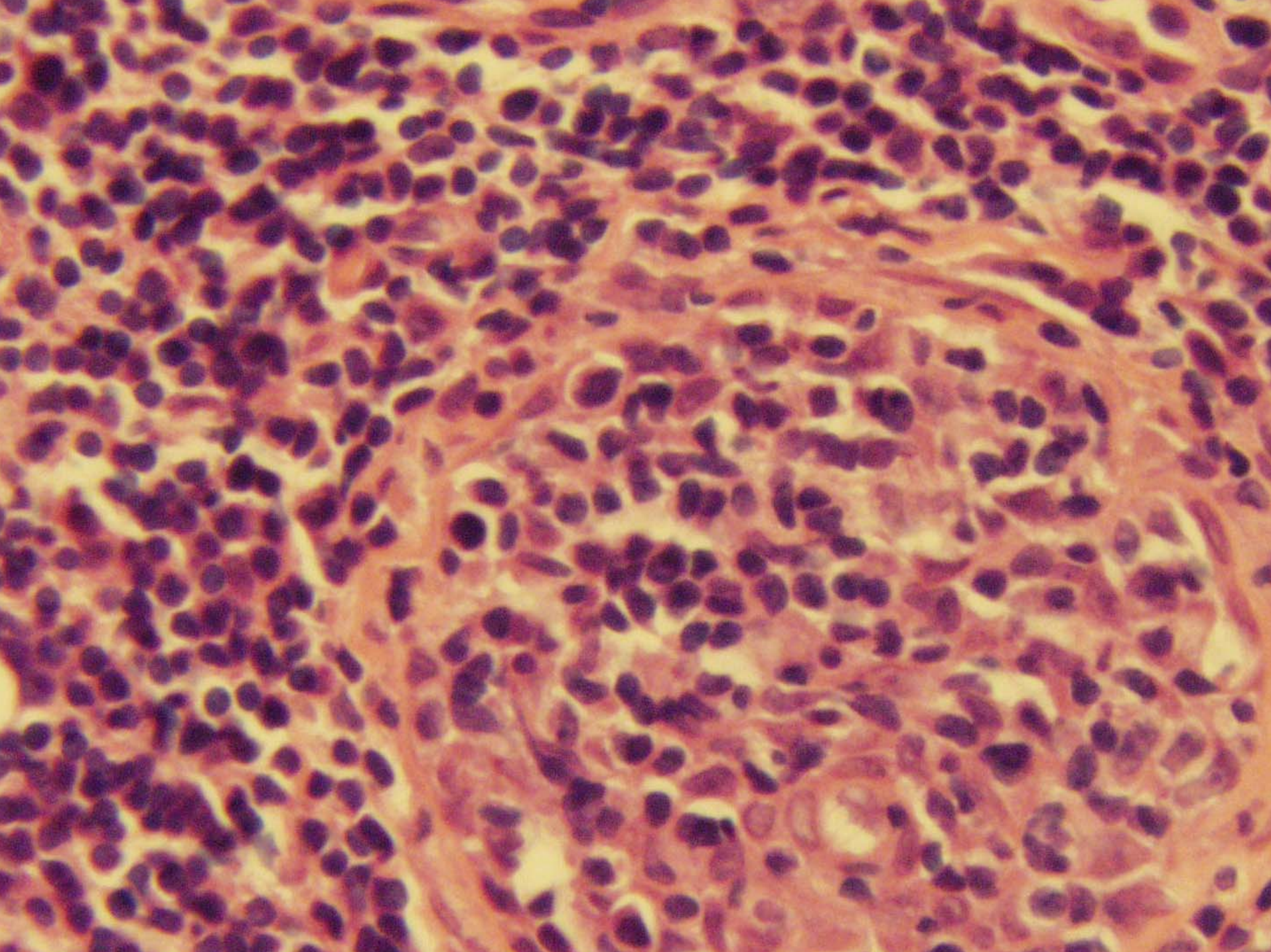










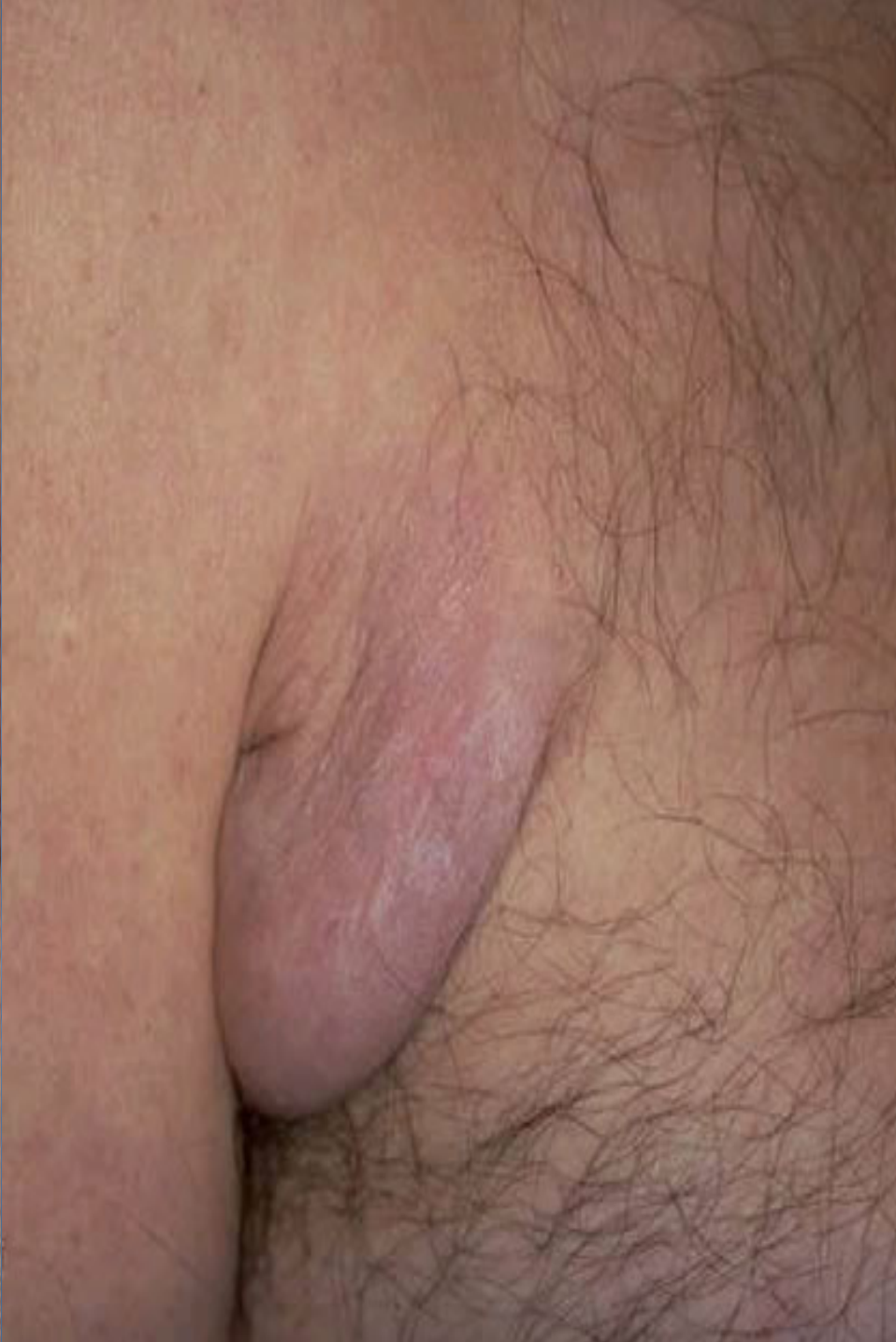
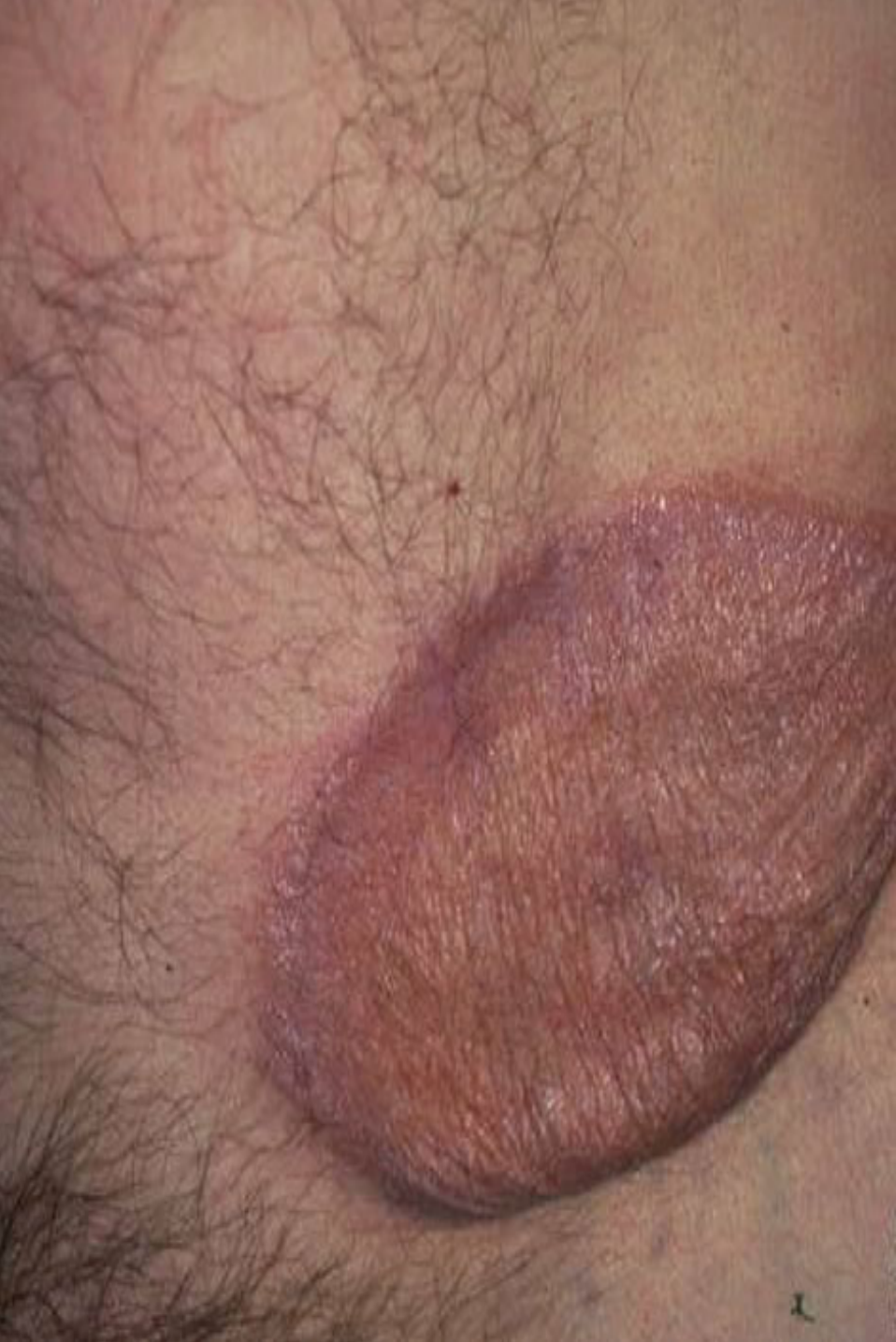


# Follicular MF

- Clinical
  - Follicular papules and comedones
  - May represent spectrum with follicular mucinosis
- Cysts and comedones infiltrated by atypical lymphocytes



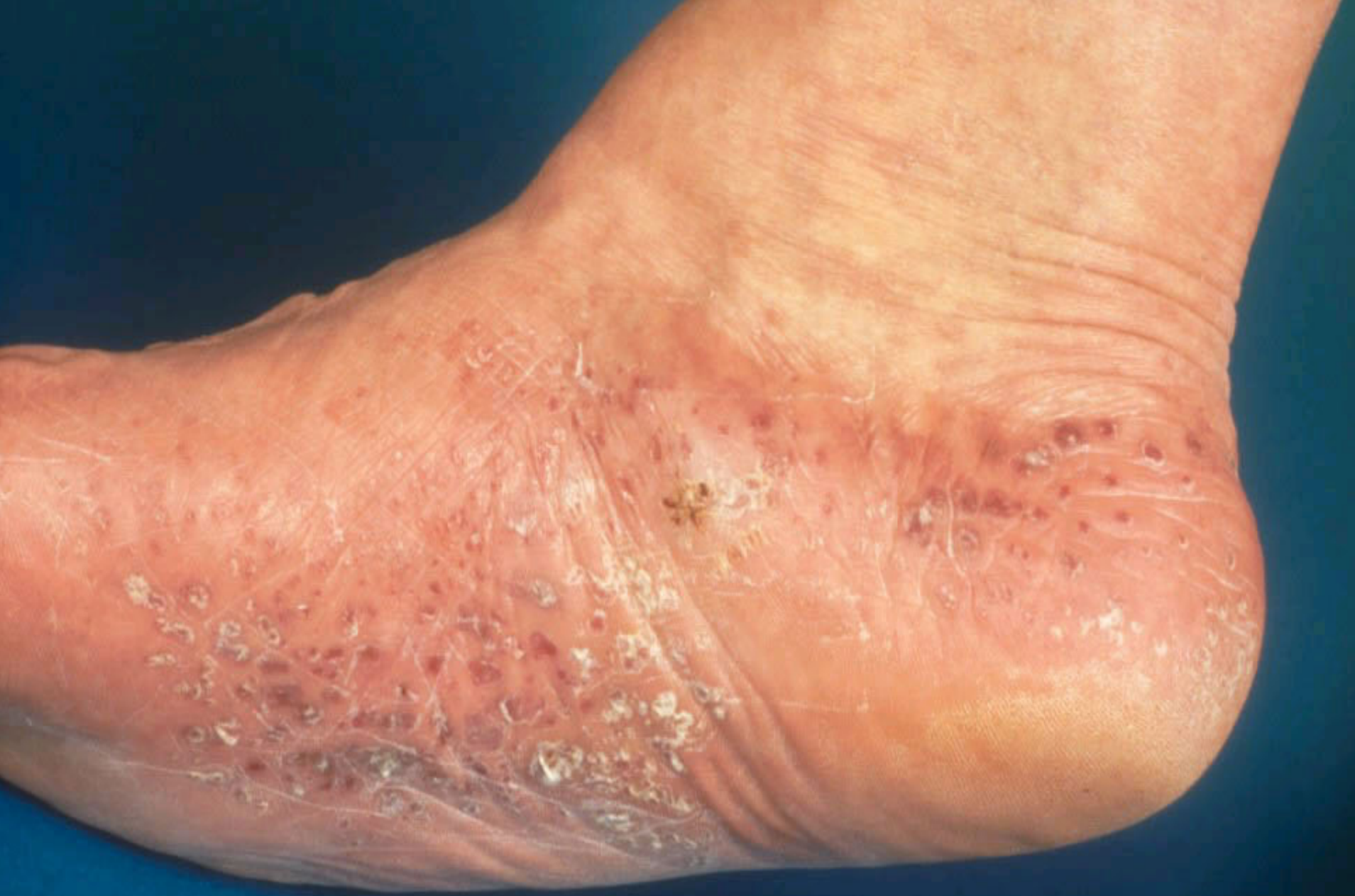



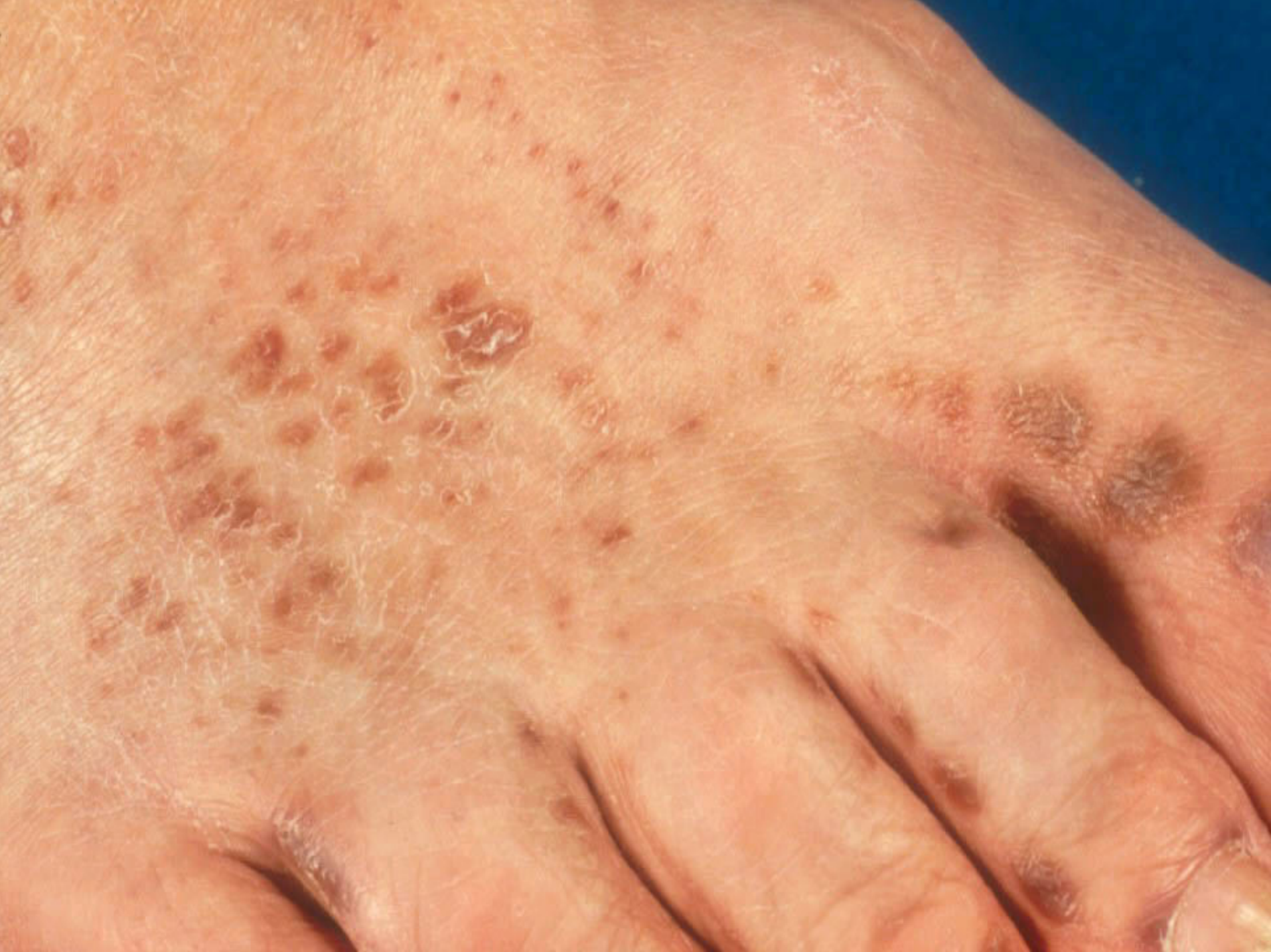# Granulomatous MF

- Noncaseating granulomas with occasional giant cells admixed with atypical lymphocytes
- Granulomatous slack skin may be a variant, differ by clinical appearance
- No prognostic significance

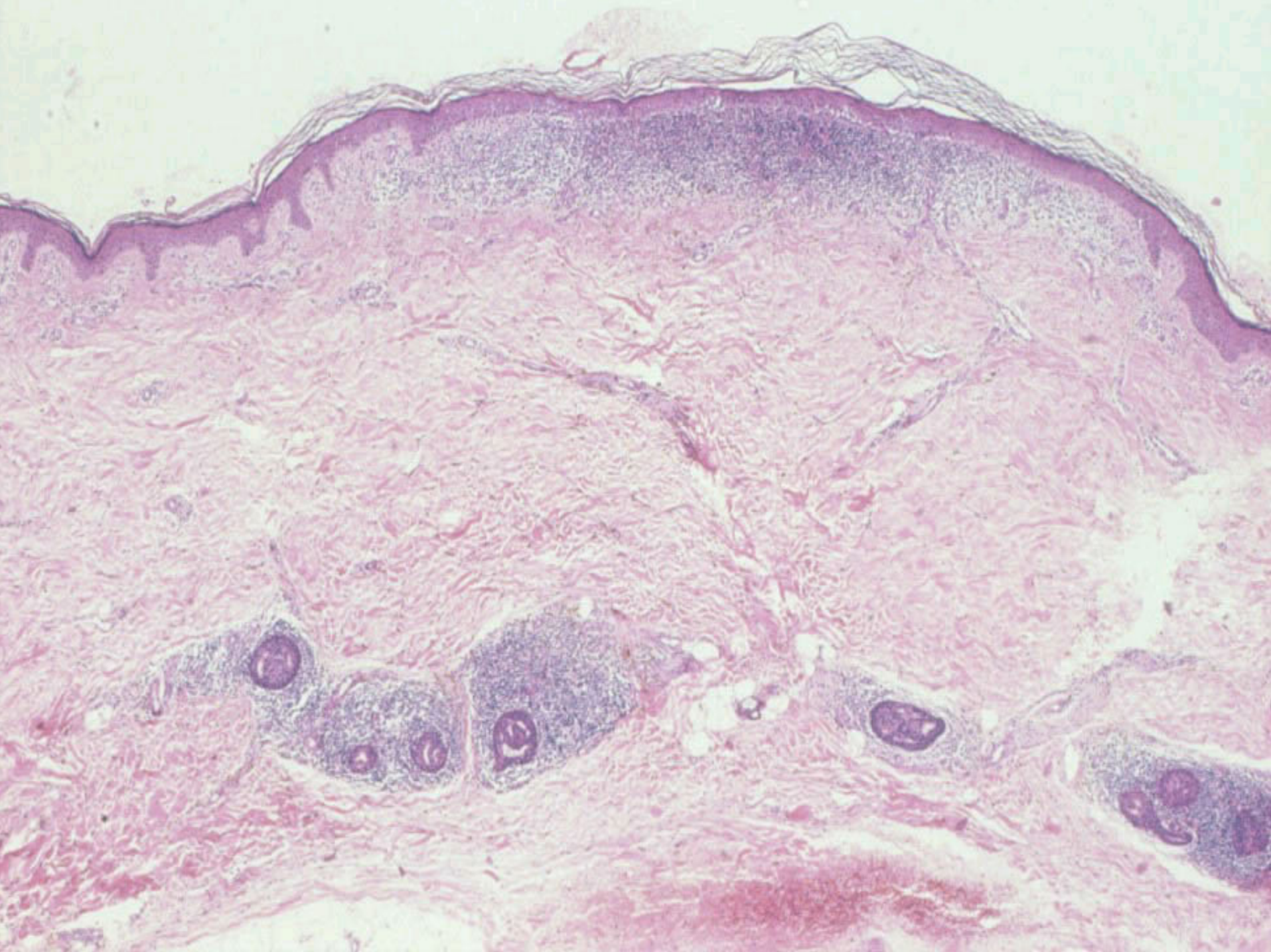




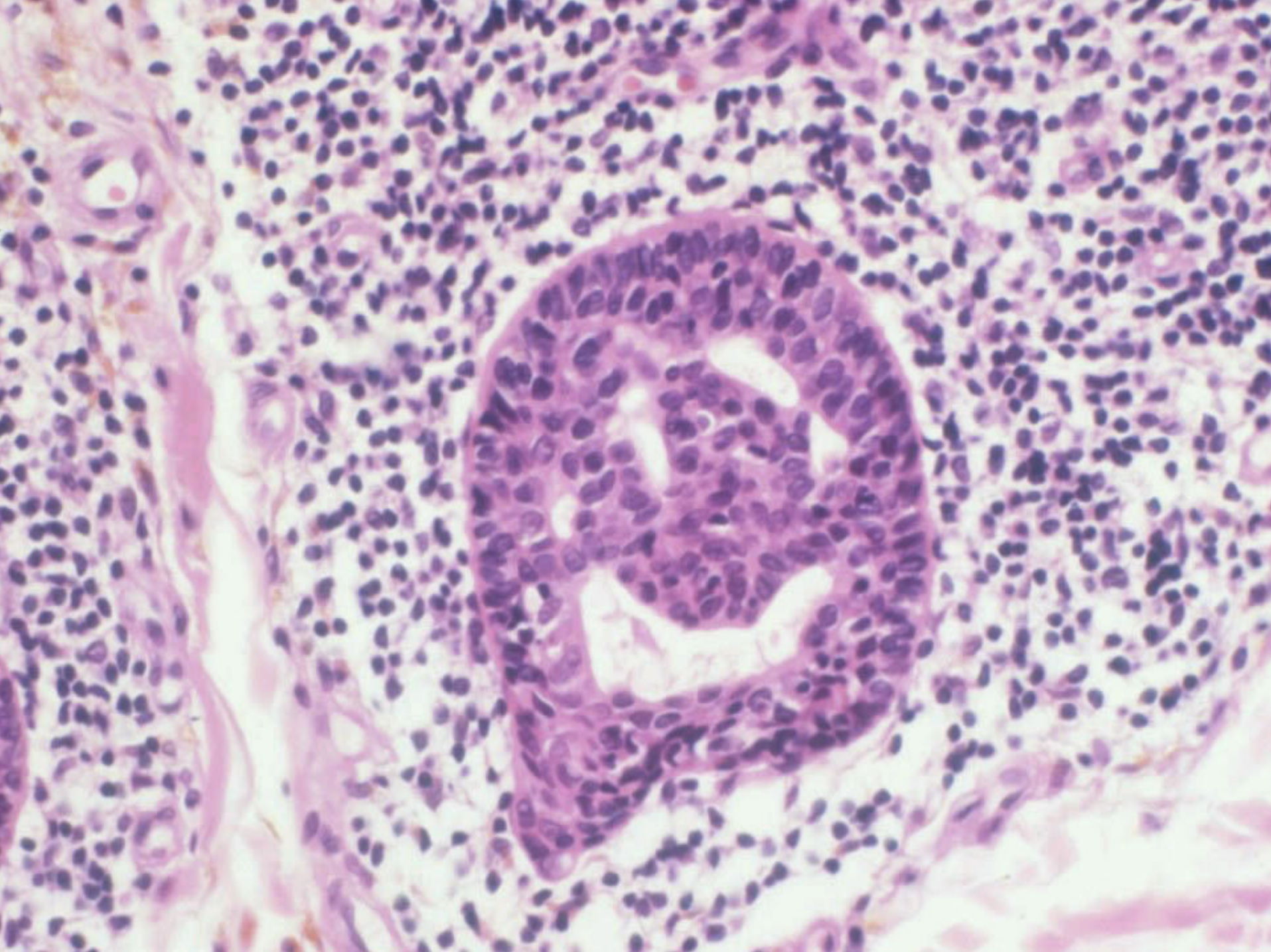














# Syringotropic MF

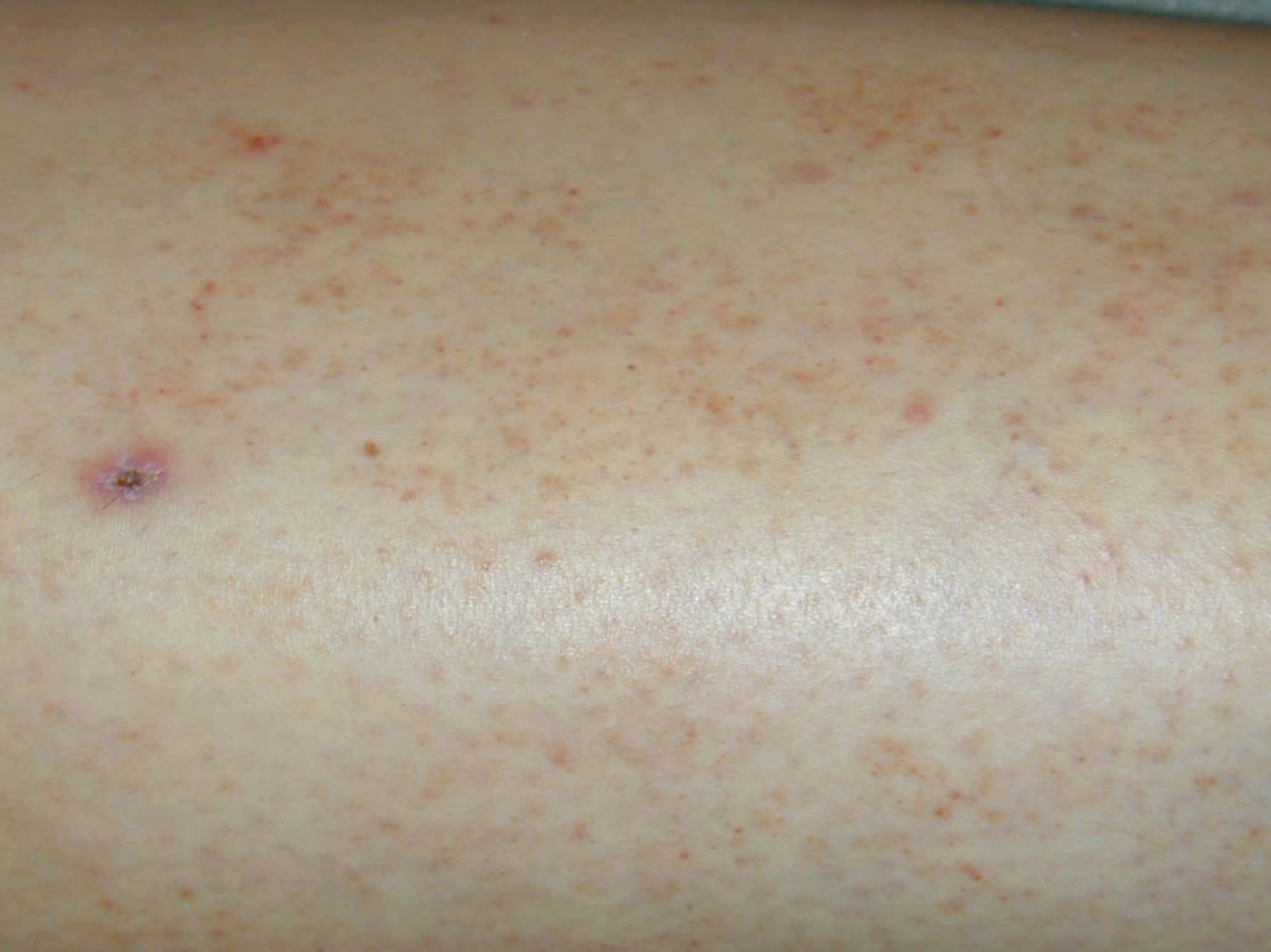- Hyperpigmented hairless patches or plaques with tiny follicular papules (Syringolymphoid hyperplasia with alopecia)
- Islands of hyperplastic glands infiltrated by numerous small lymphocytes
- “Eccrine spiradenoma en miniature”



# Pigmented Purpura-Like MF

- Clinically identical to PPD
- Lichenoid infiltrate with hemosiderin granules and extravasated rbcs



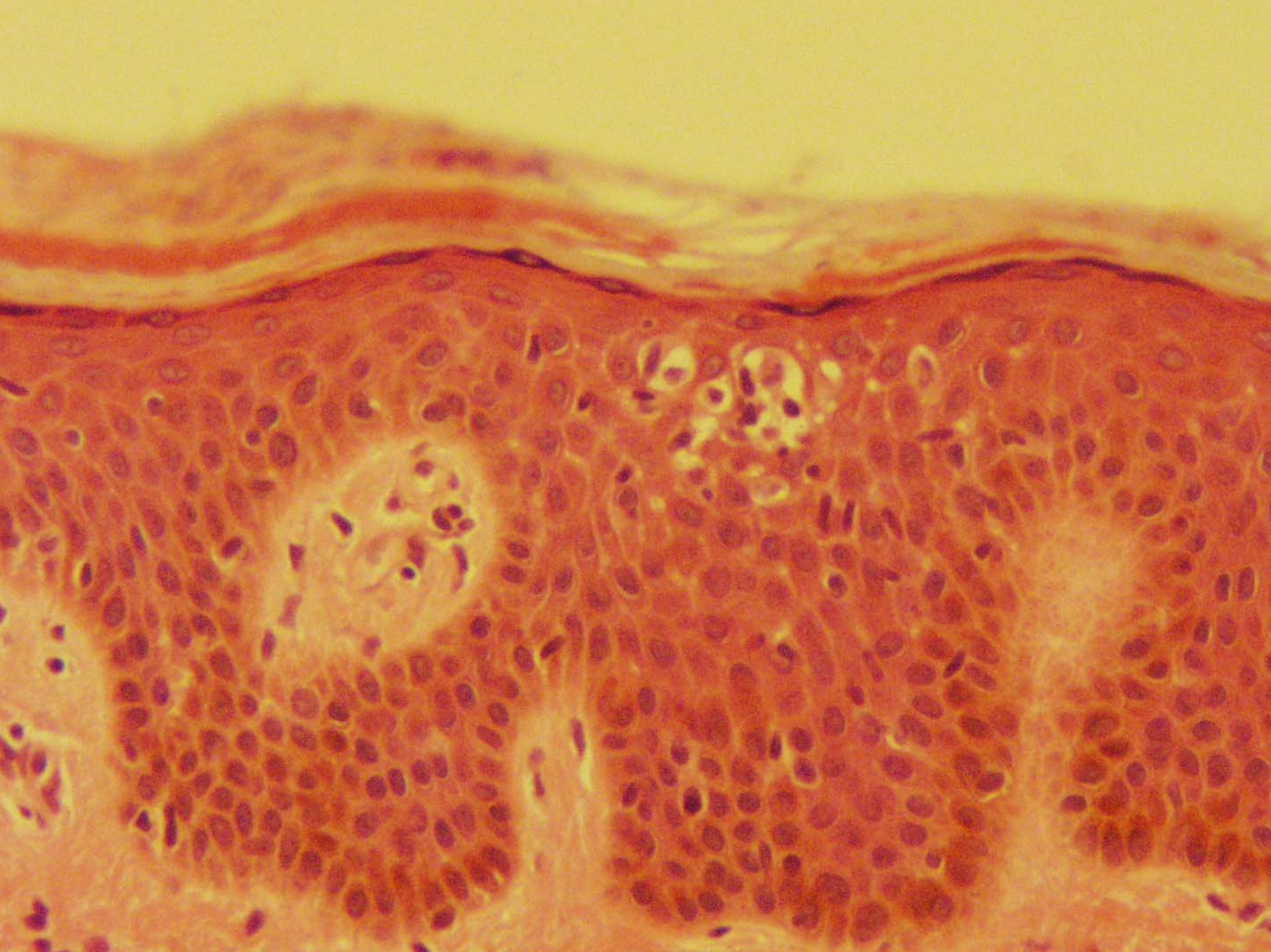




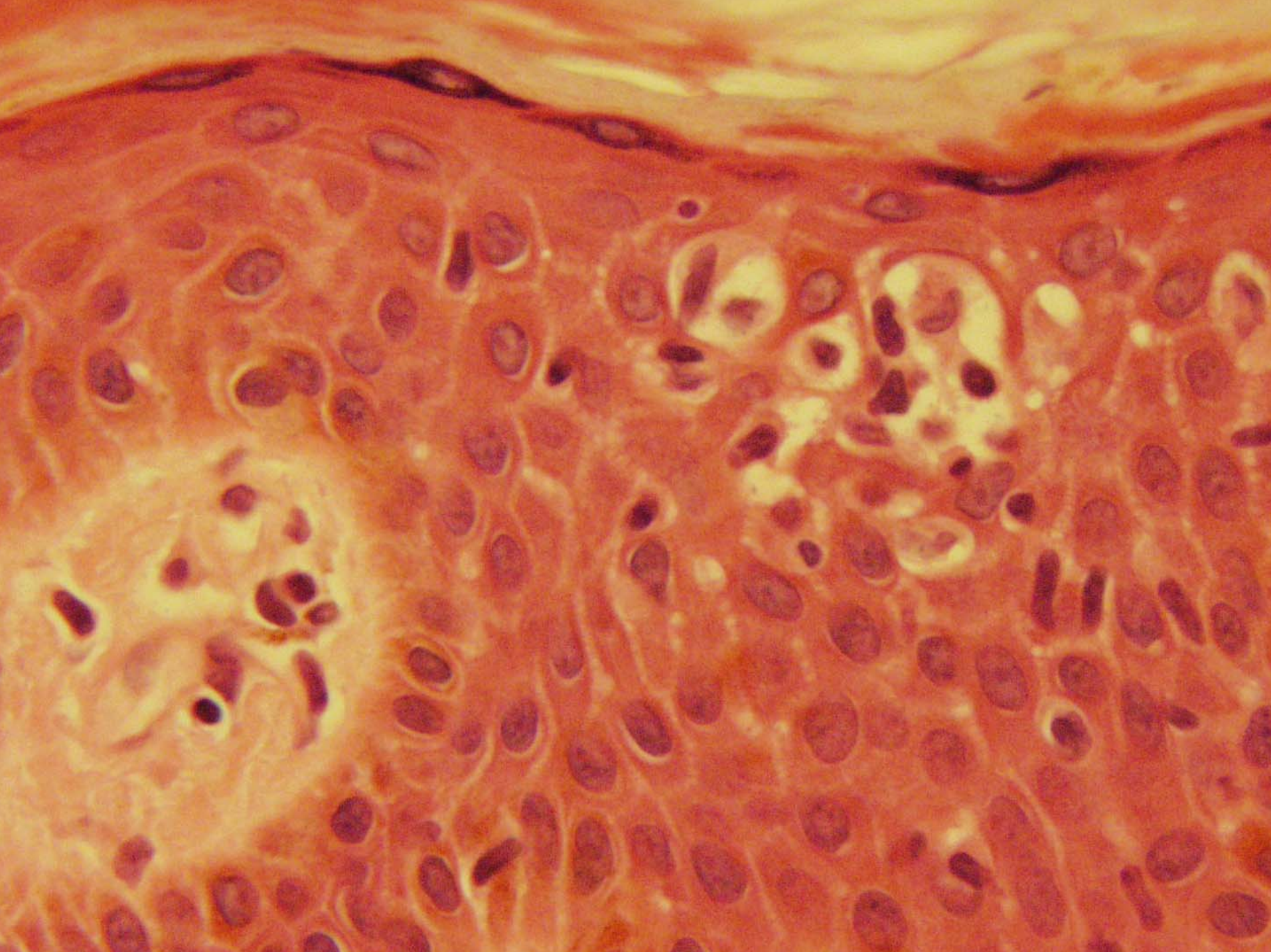
# Differential Diagnosis

- Pseudo-Pautrier Microabscesses
- Chronic Dermatitis
- Lymphomatoid Drug Eruptions
- CBCL
- Leukemia cutis
- Adult T-cell leukemia/lymphoma (HTLV-1)





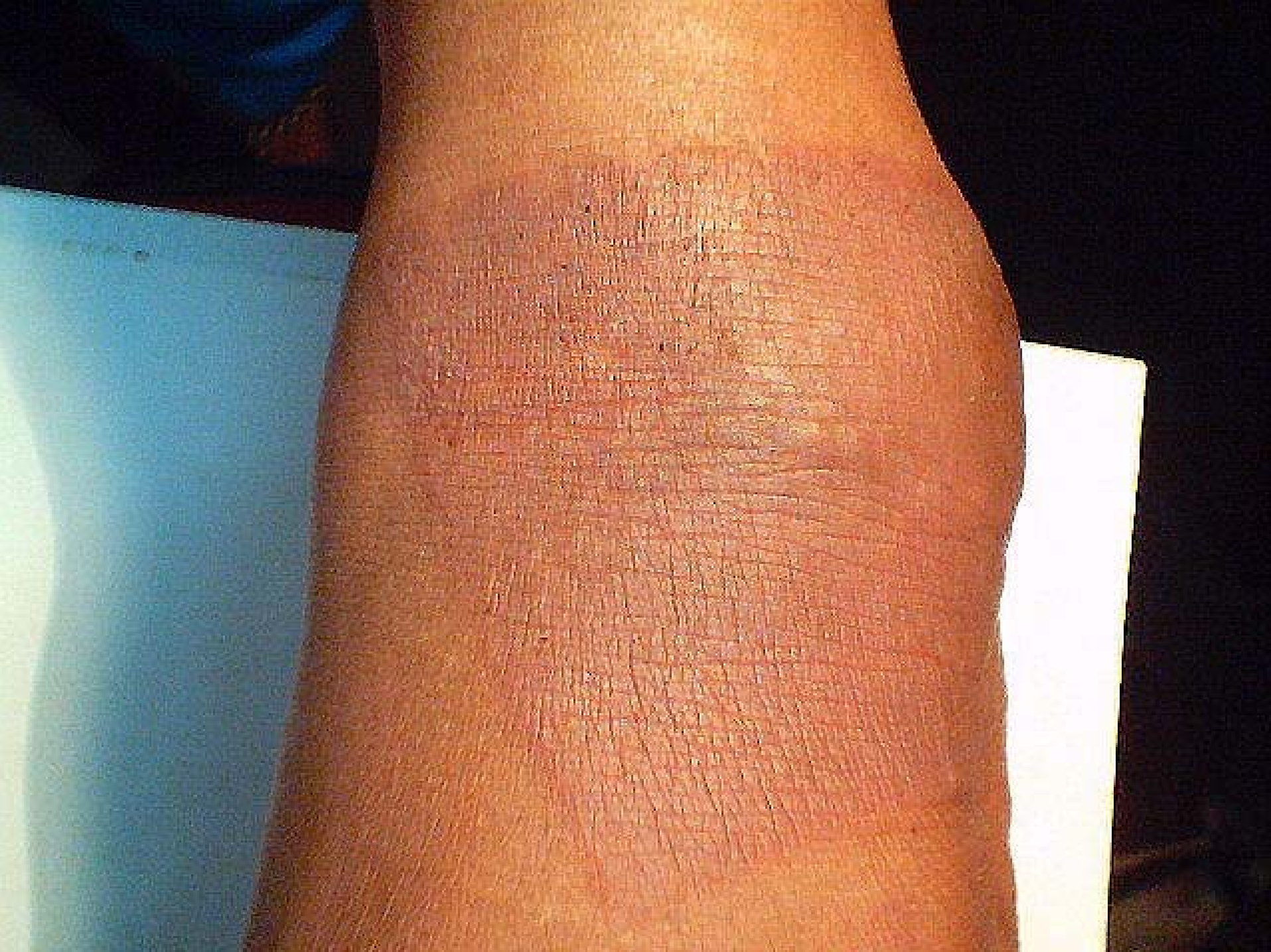



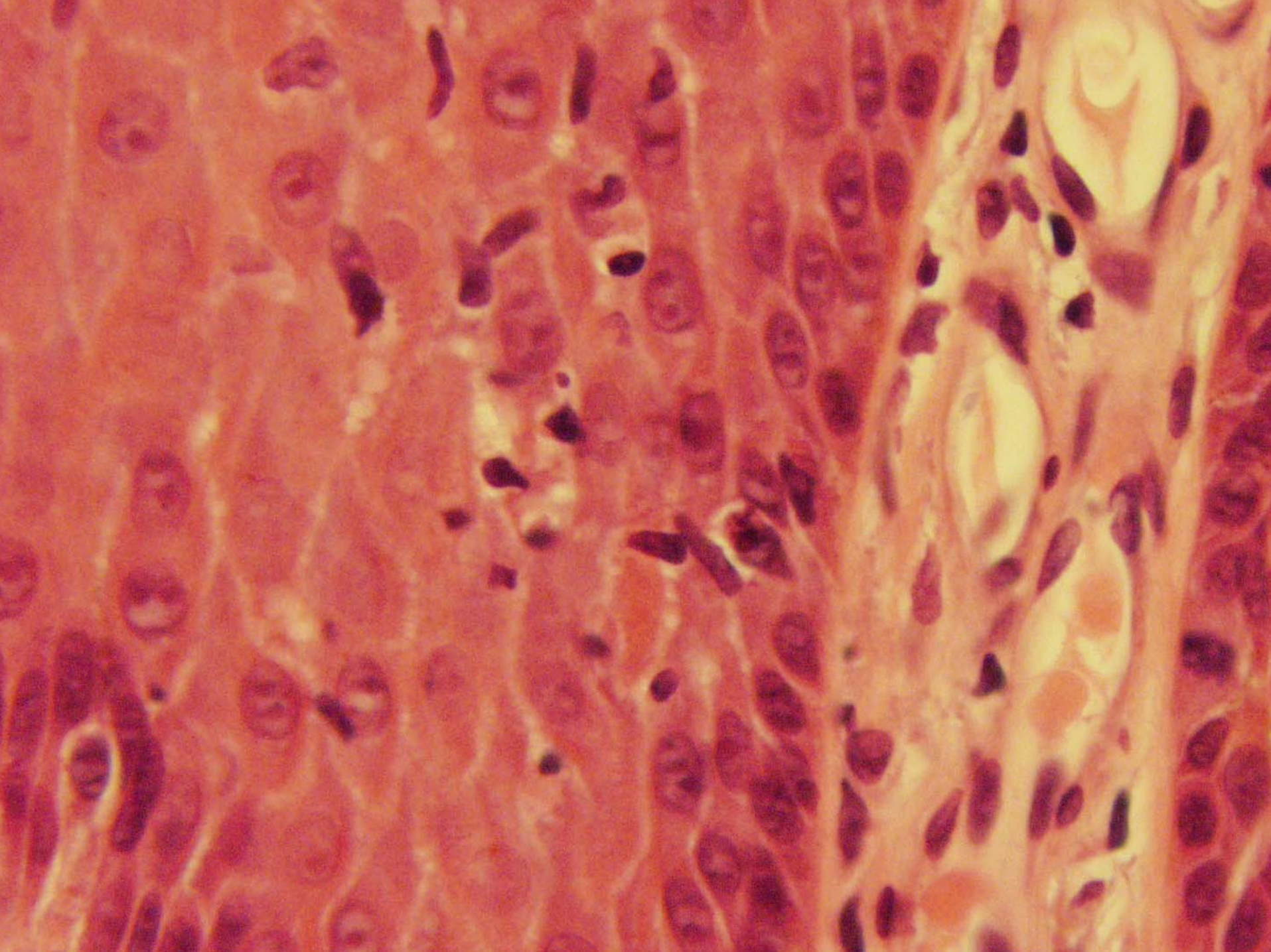


# Allergic Contact Dermatitis

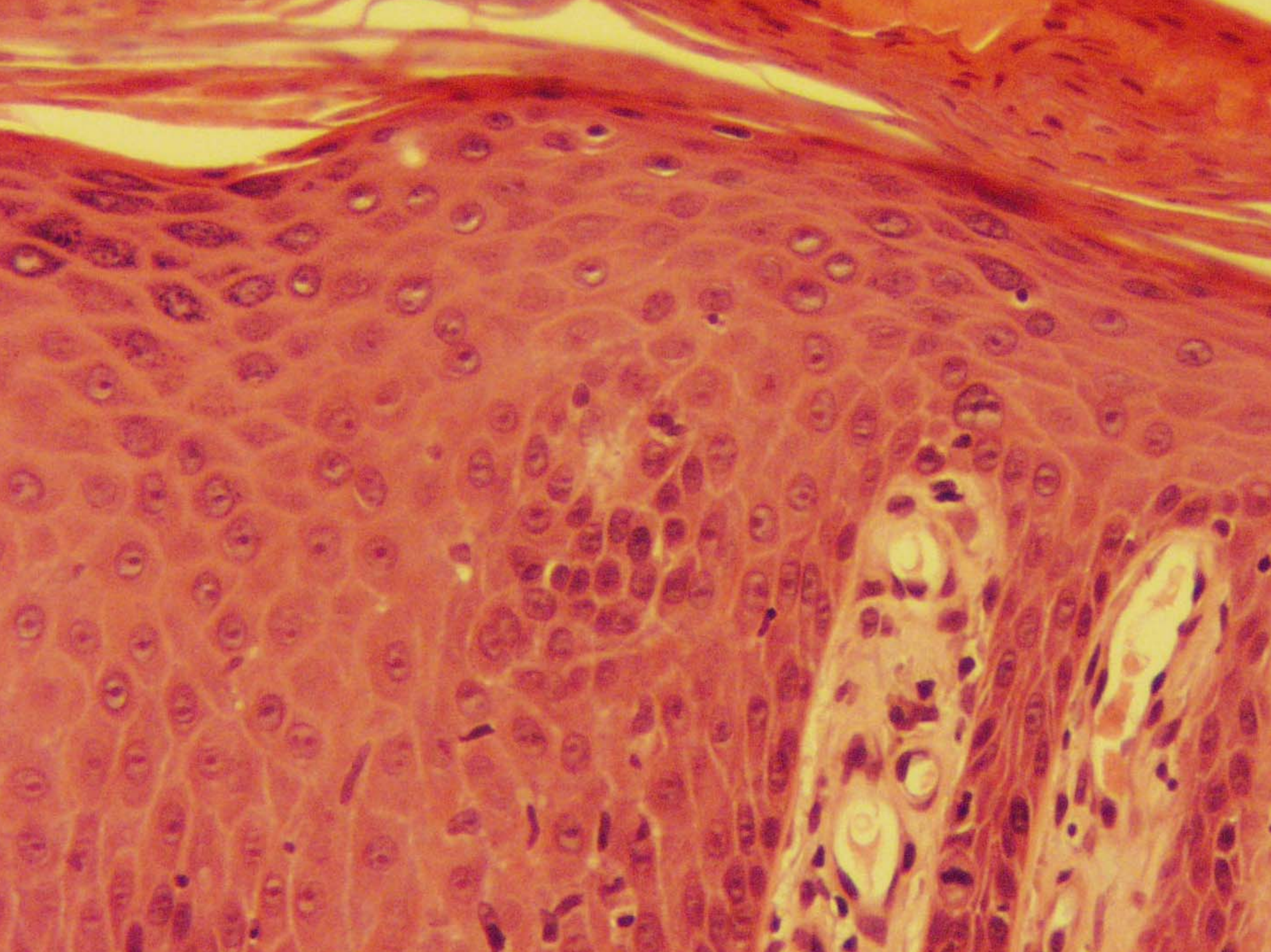




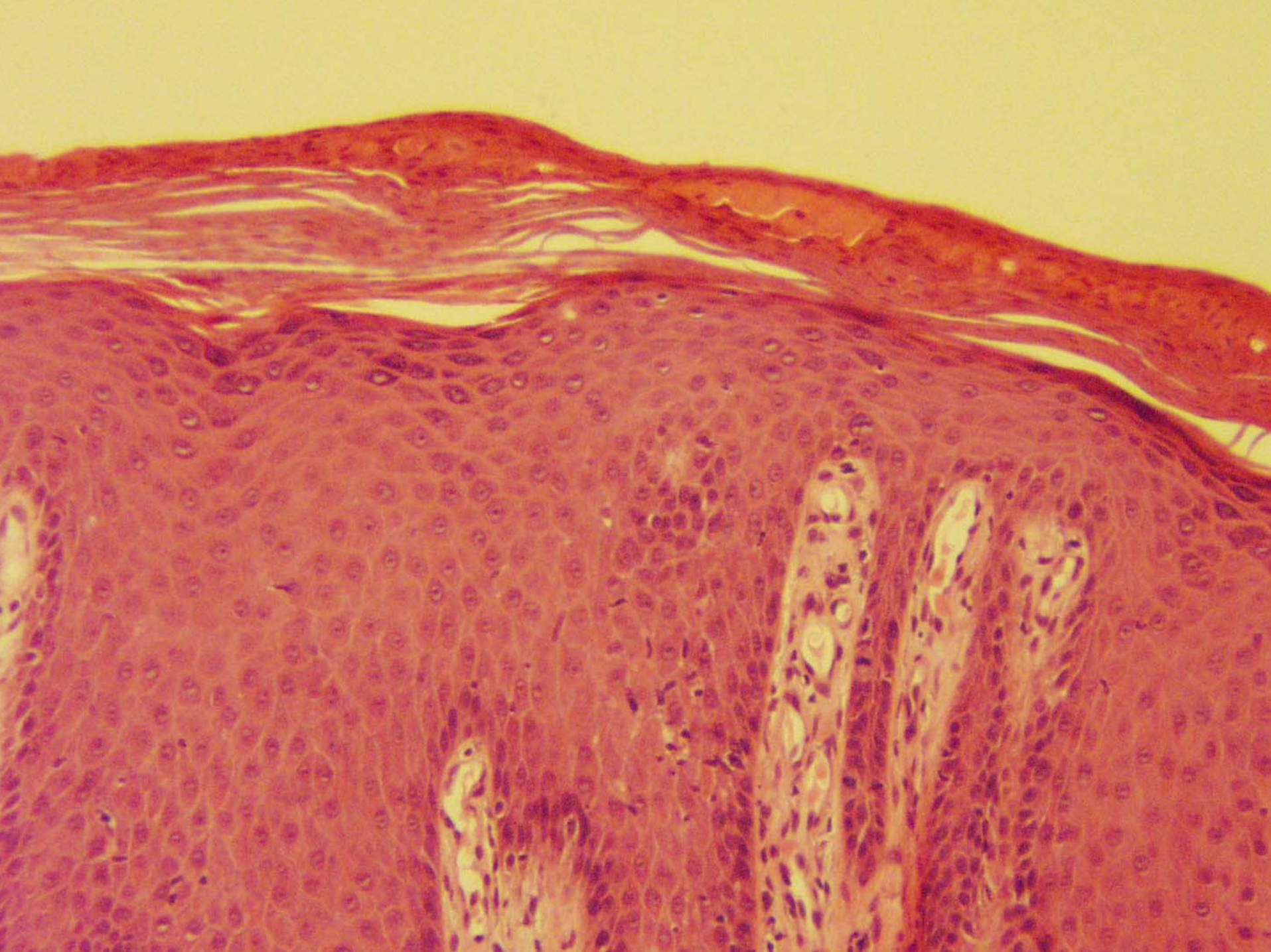








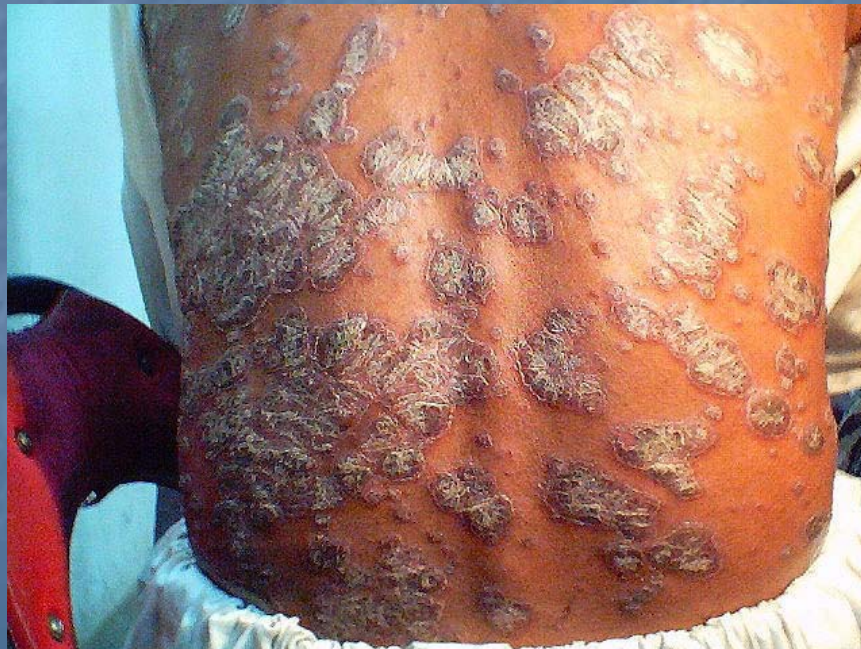
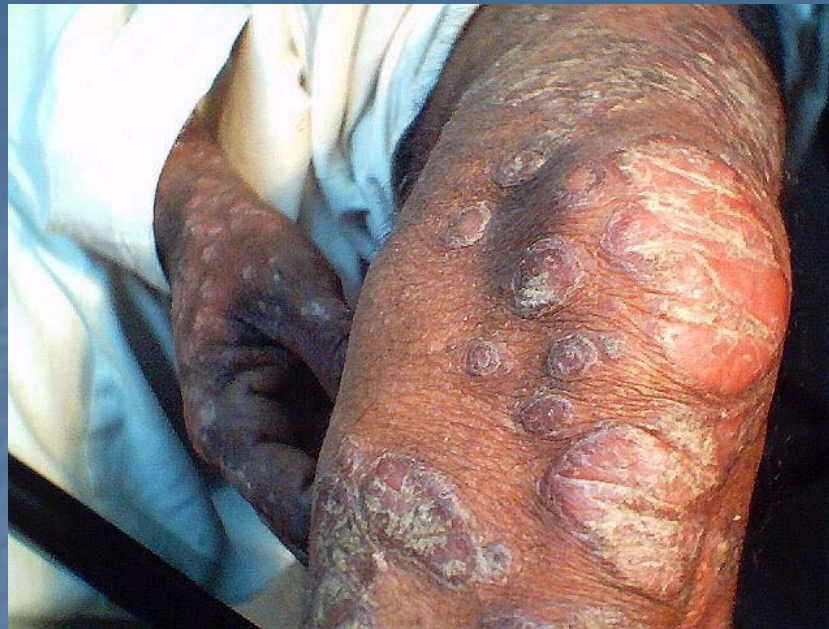


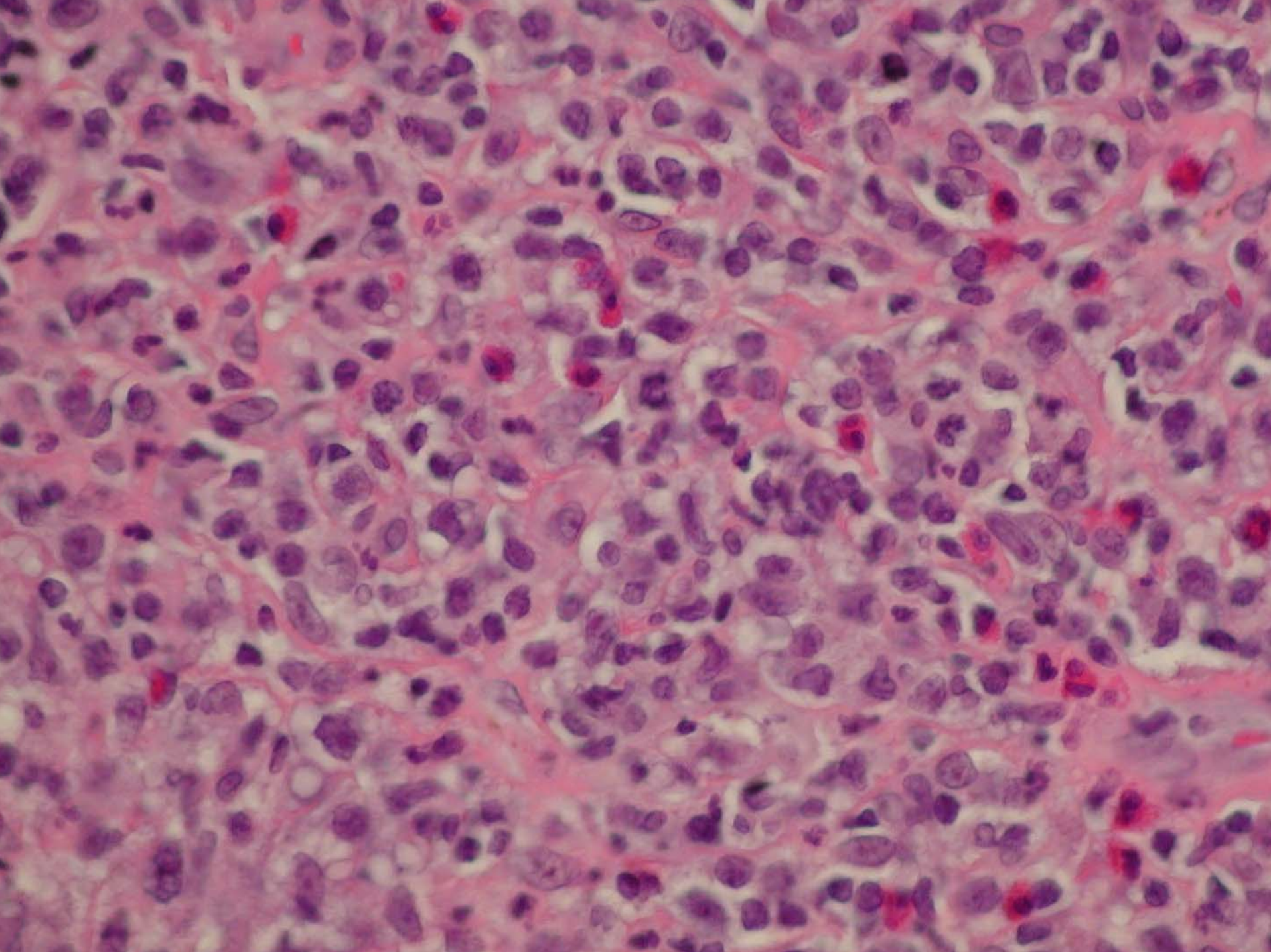


# Psoriasis Vulgaris







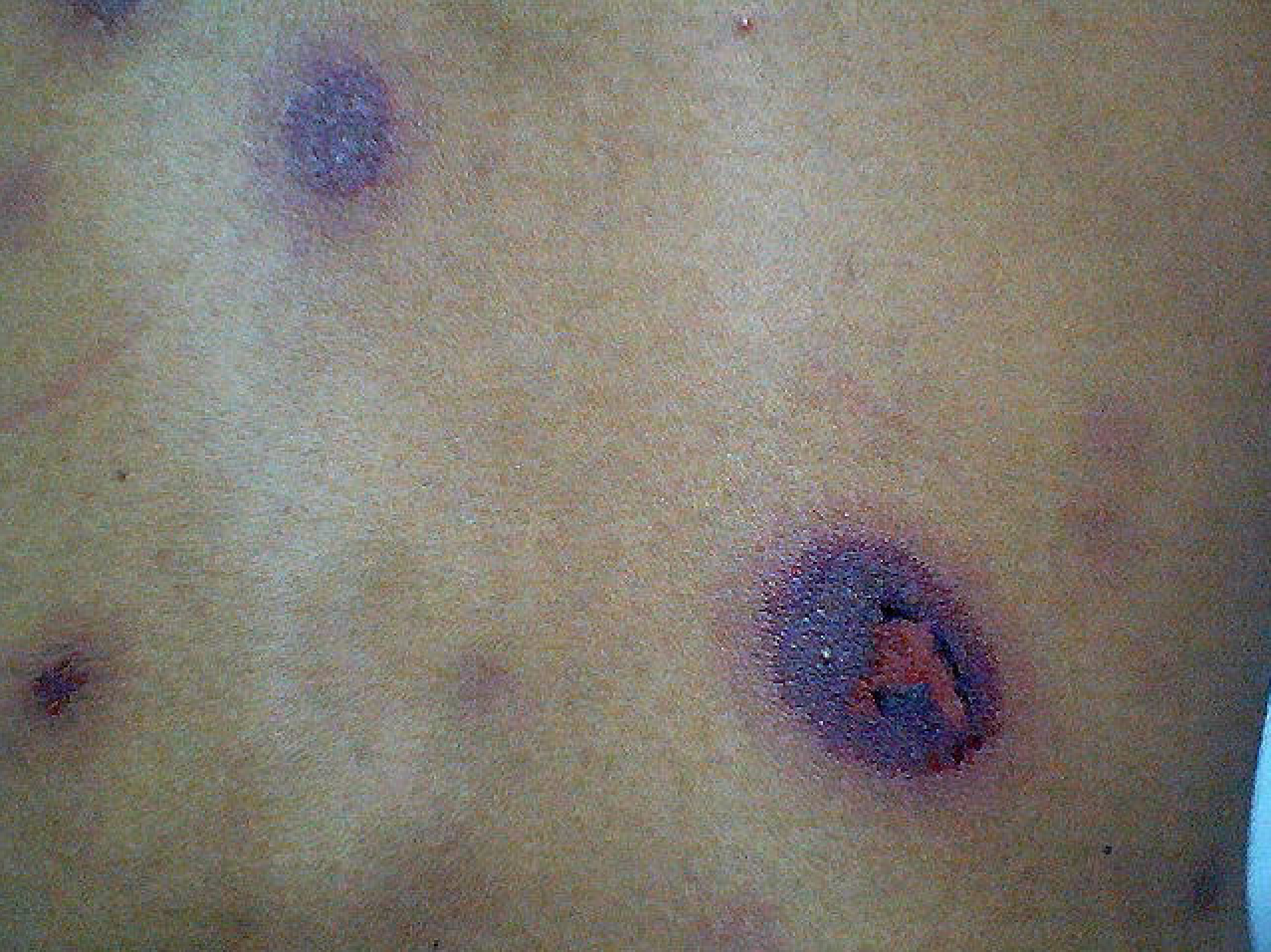



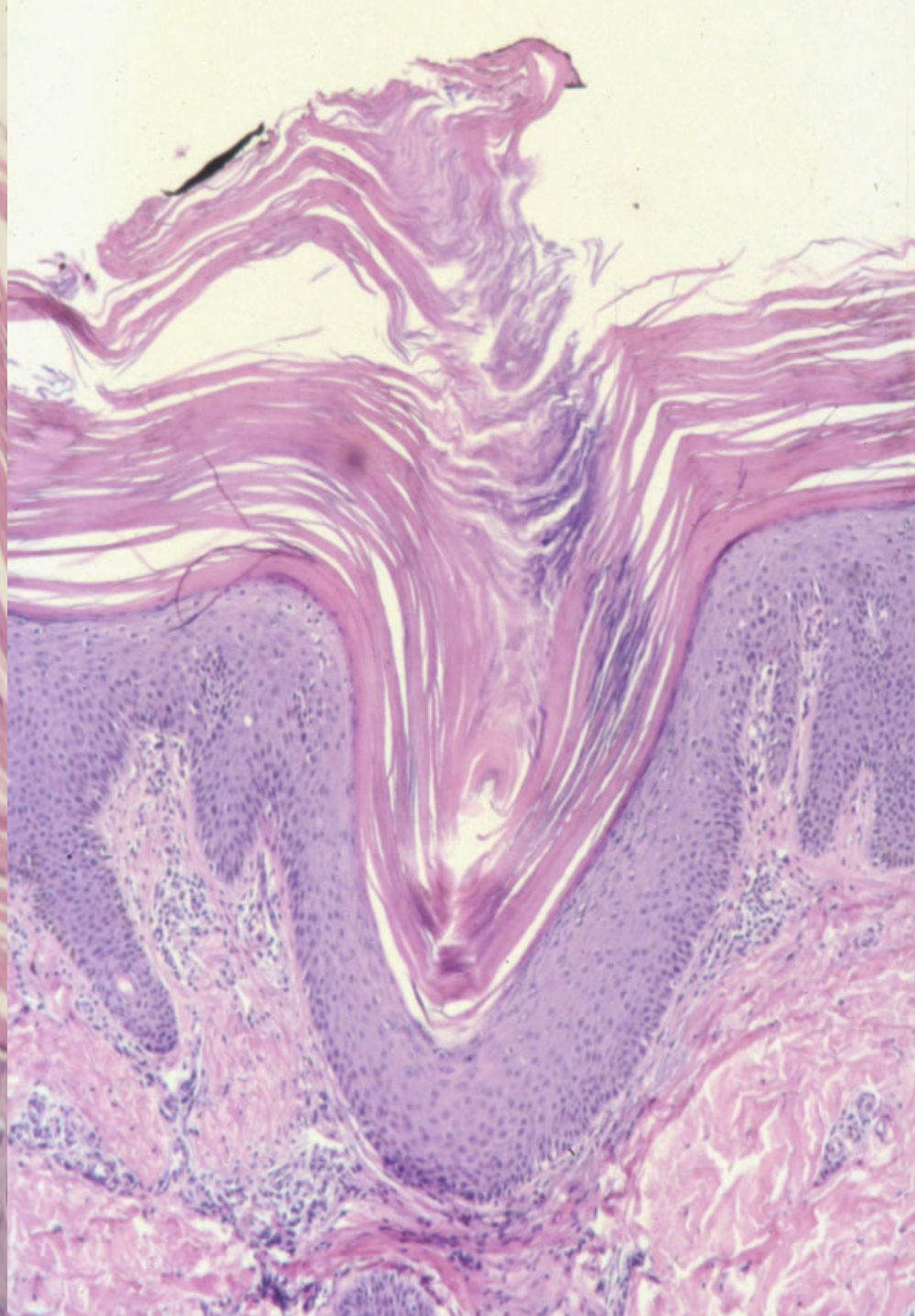
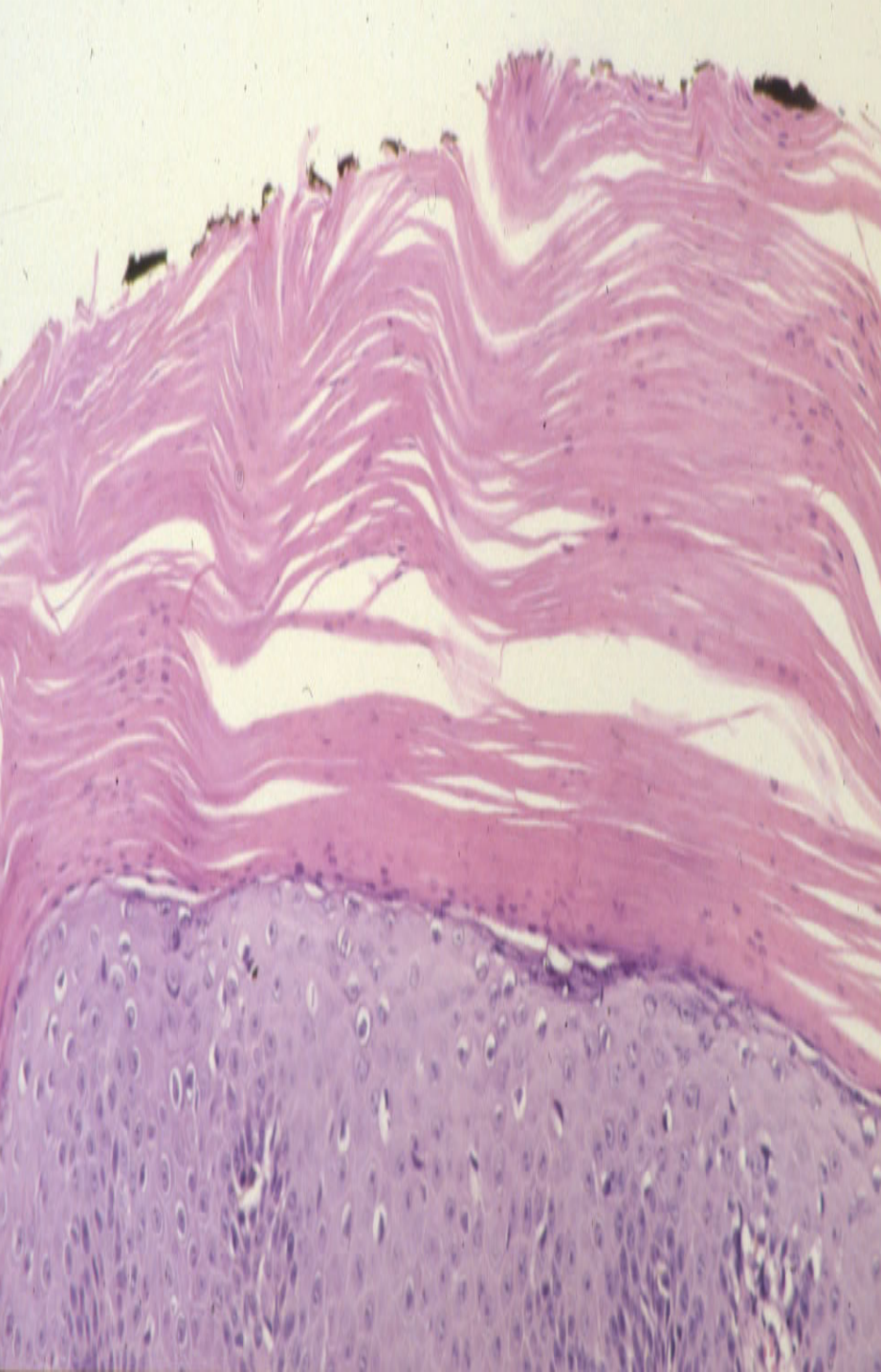
# Chronic Hypersensitivity Reaction

- Lymphomatoid drug eruption
- Eosinophils do not exclude MF!







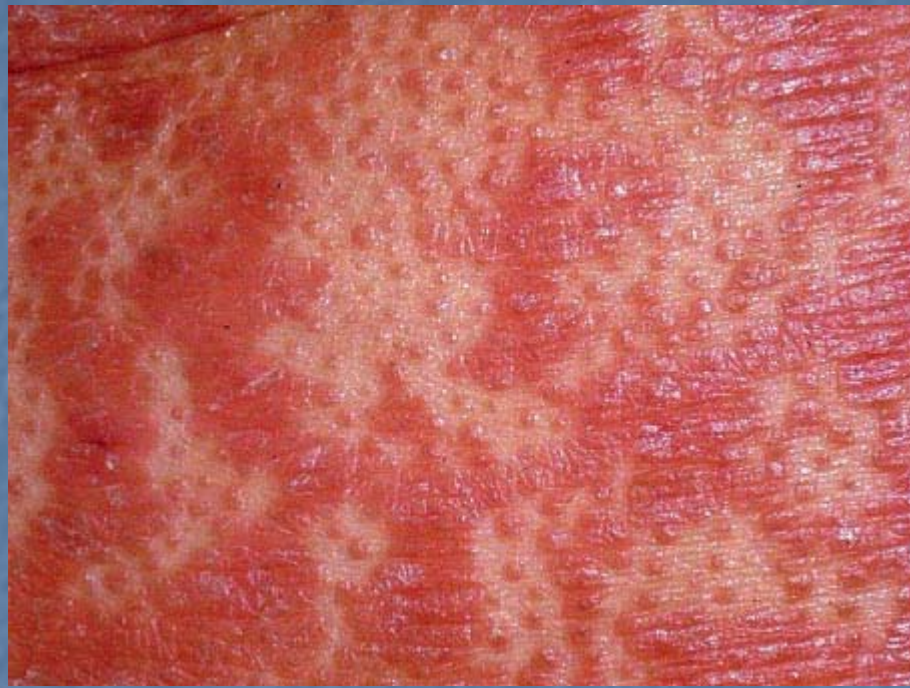
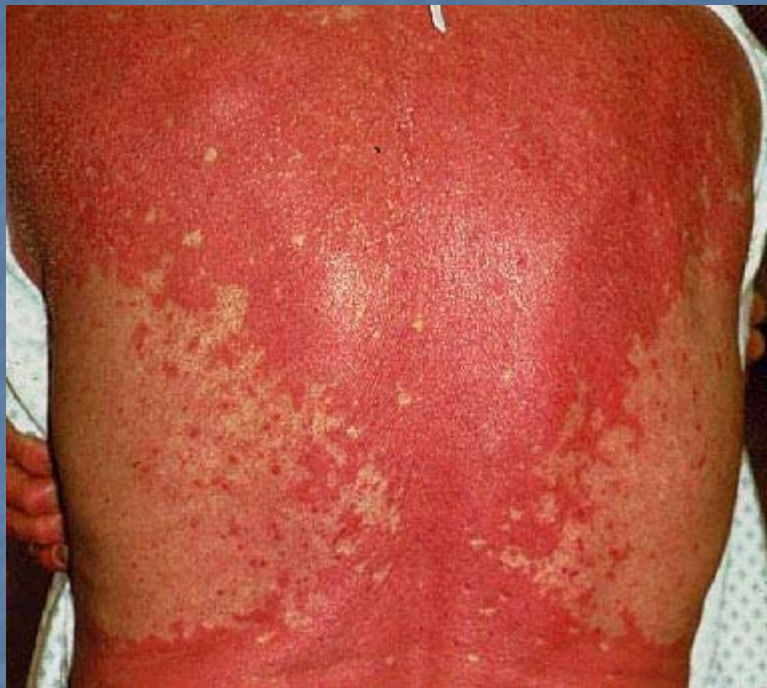


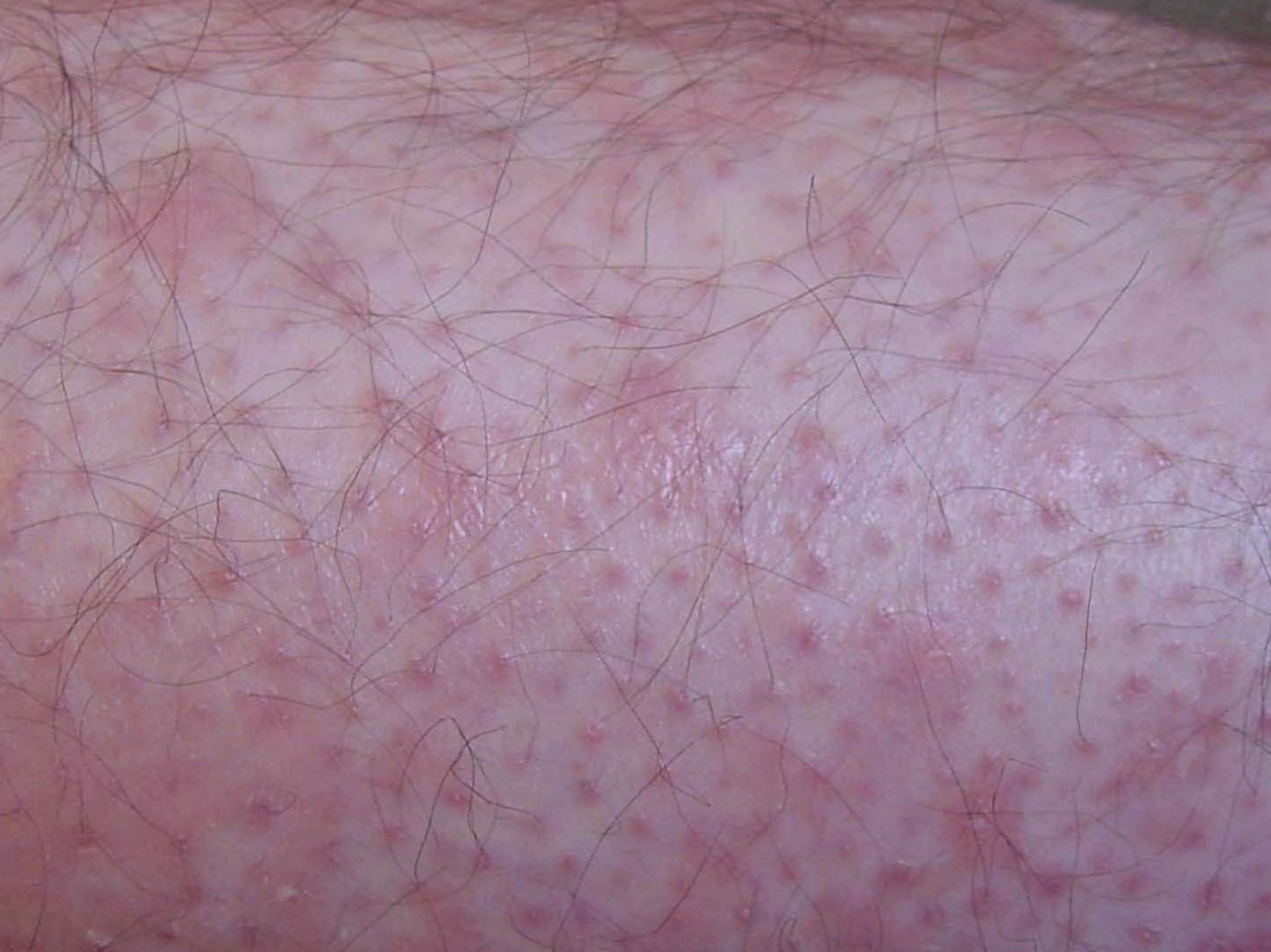# Pityriasis Rubra Pilaris

- Erythroderma
  - Clinical overlap with MF
- Psoriasiform dermatitis
- Alternating ortho- and para-keratosis in horizontal and vertical planes
- Follicular plugging

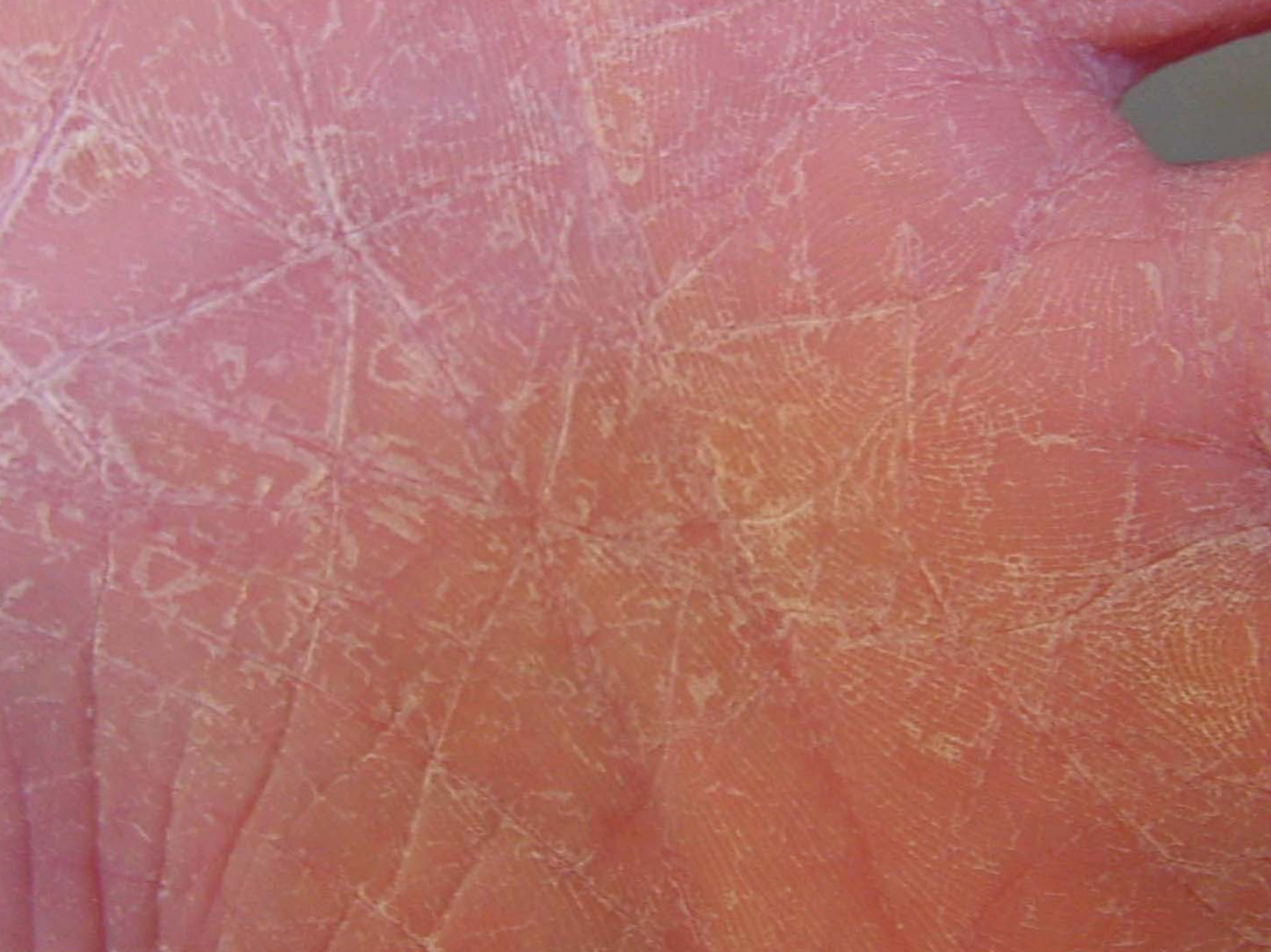



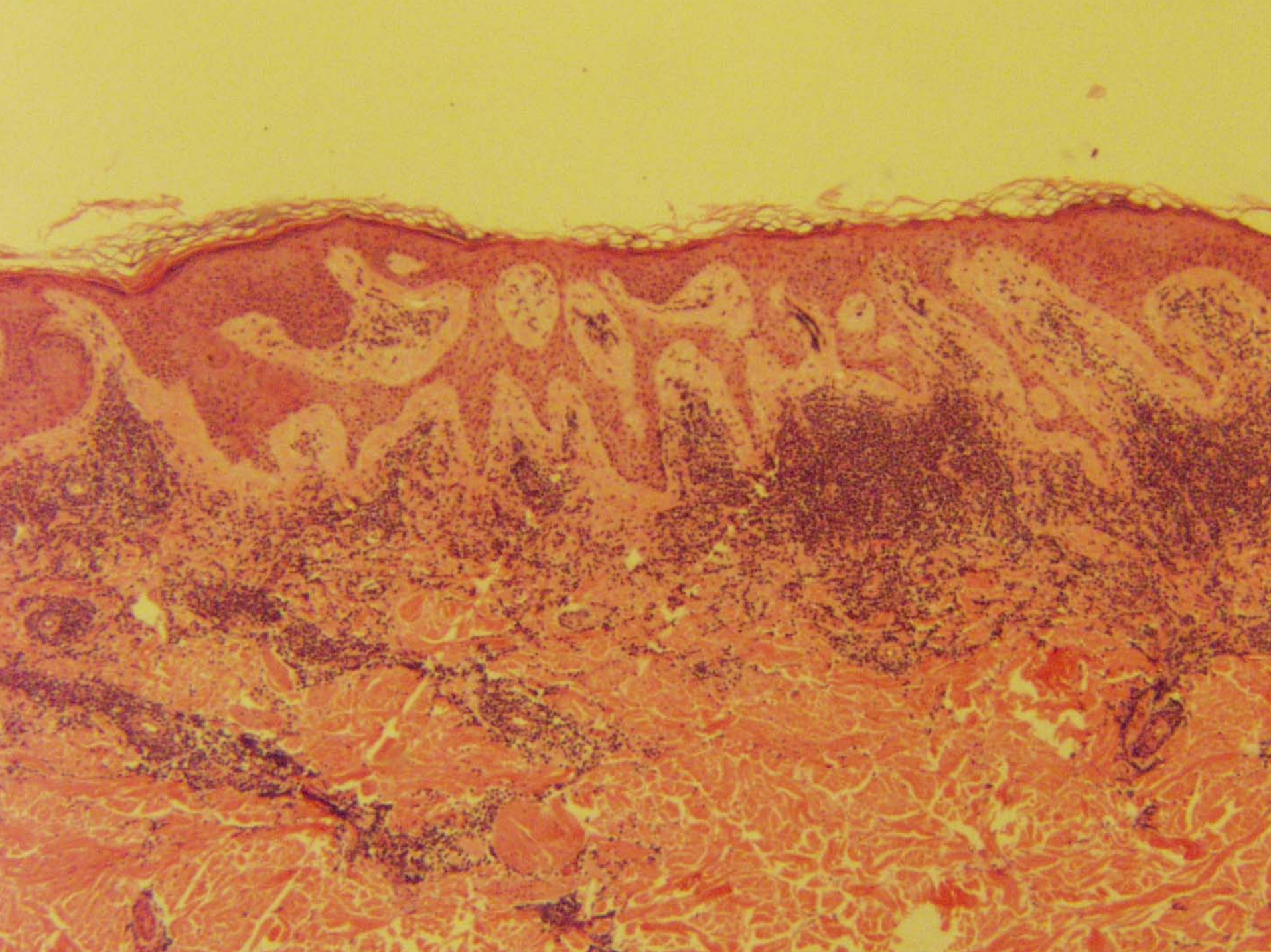




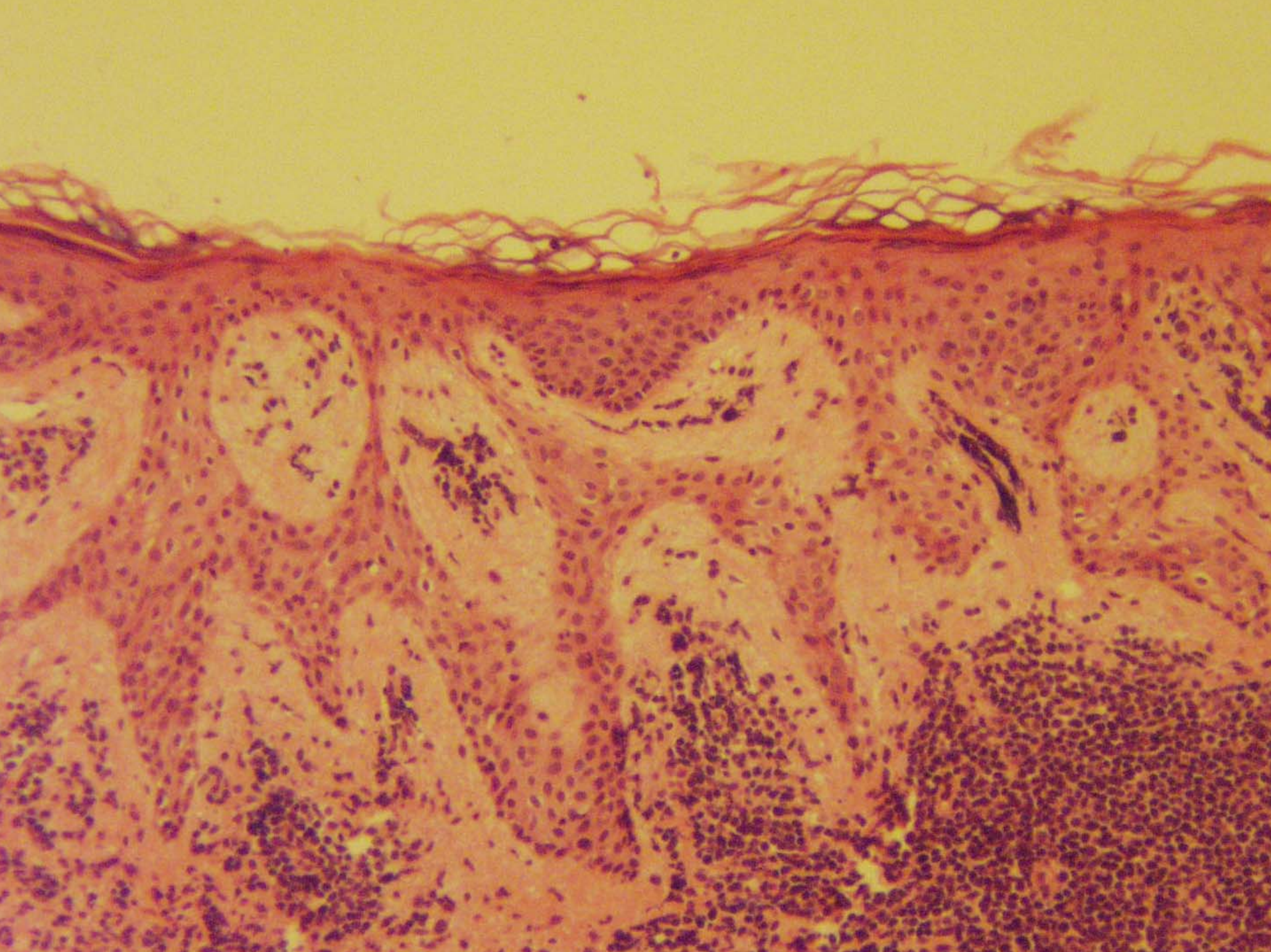




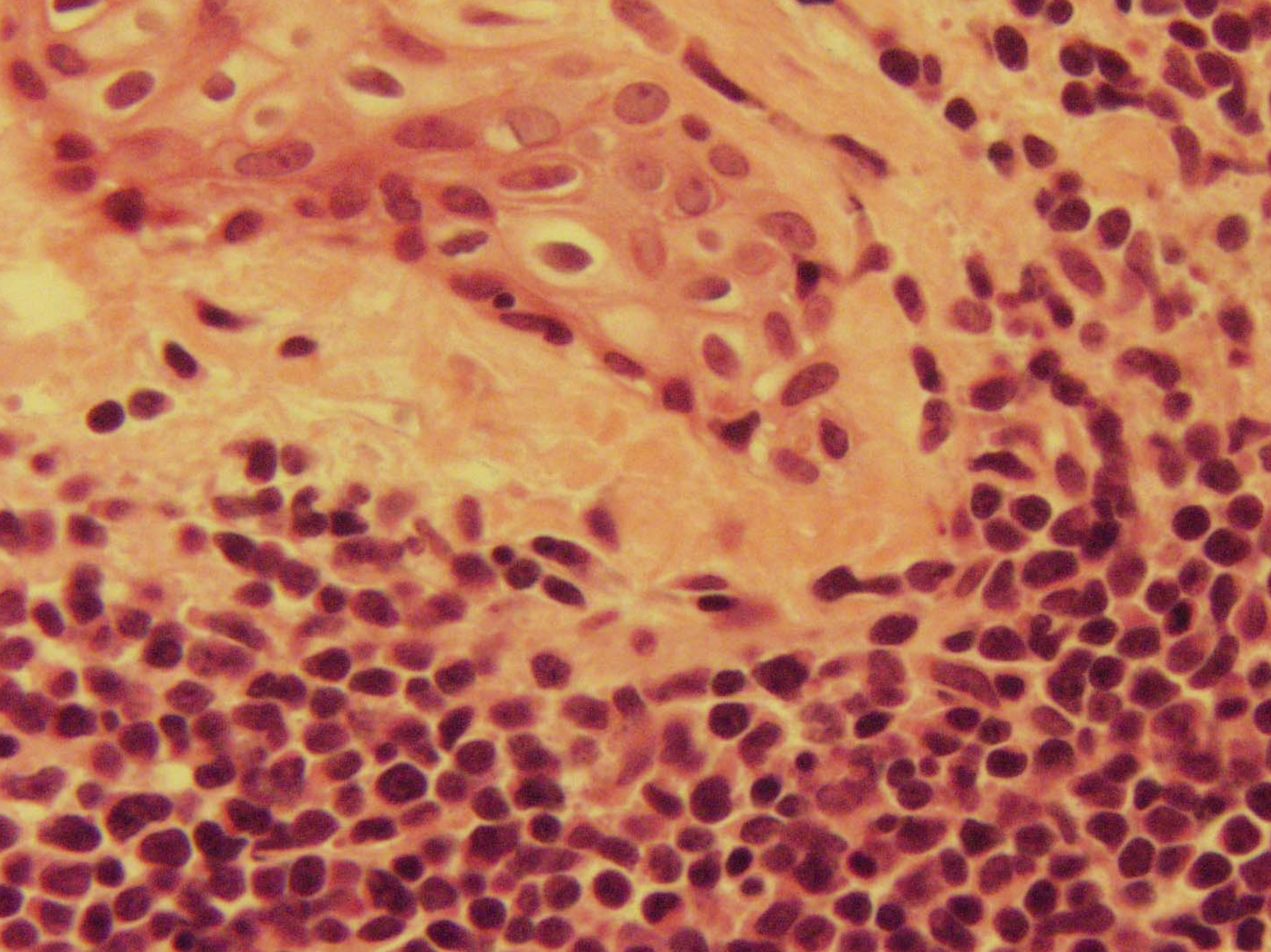




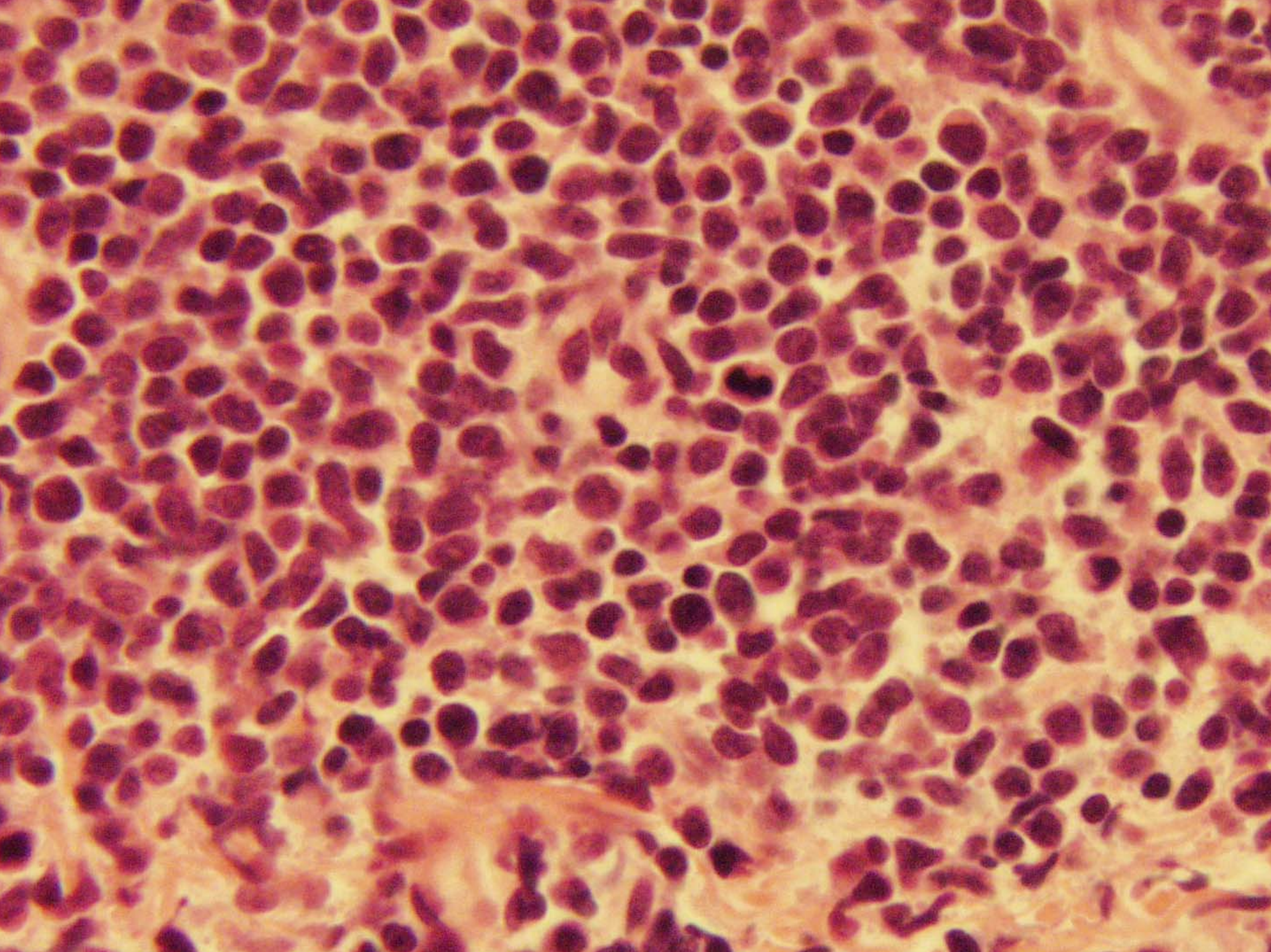




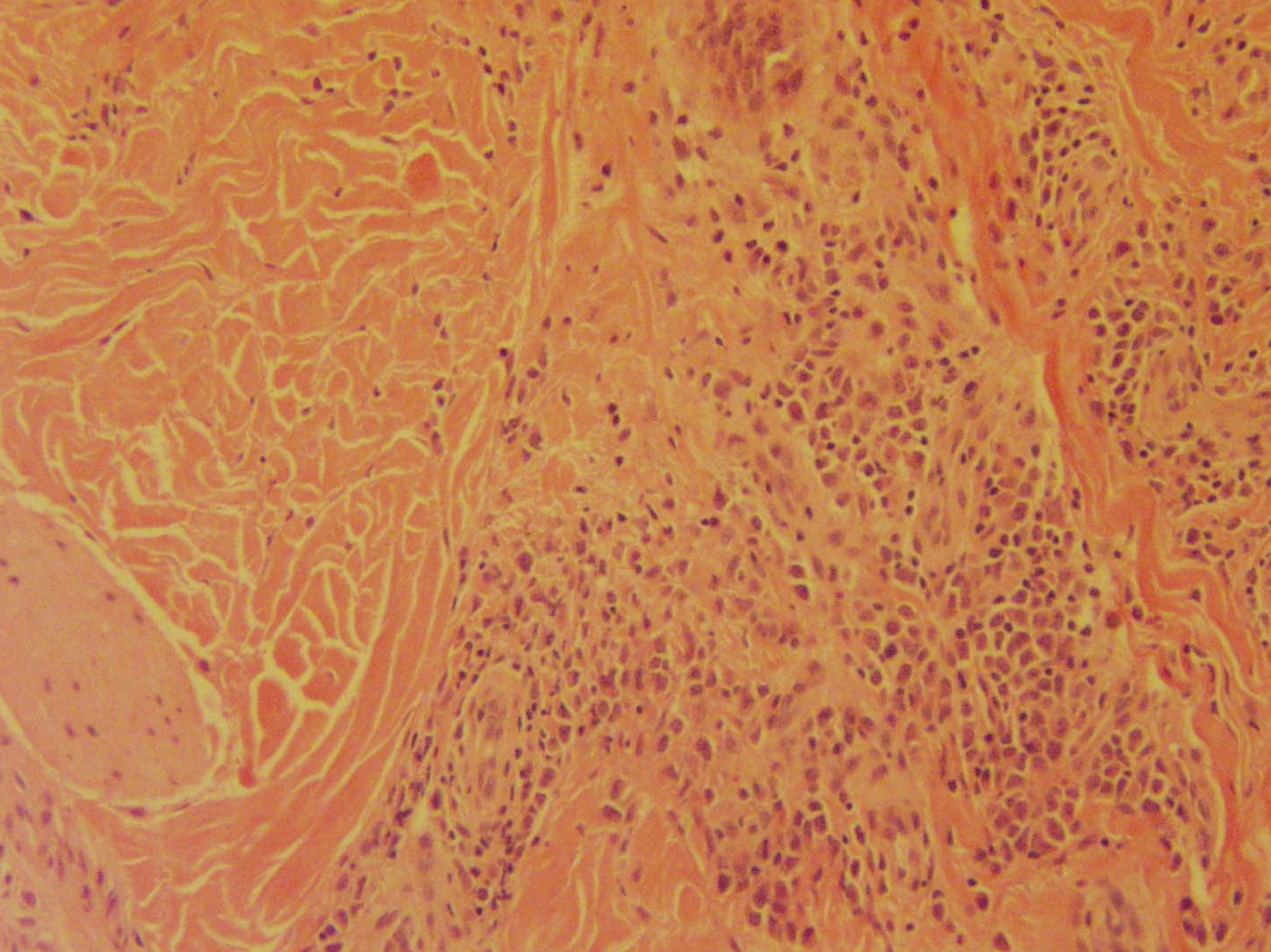




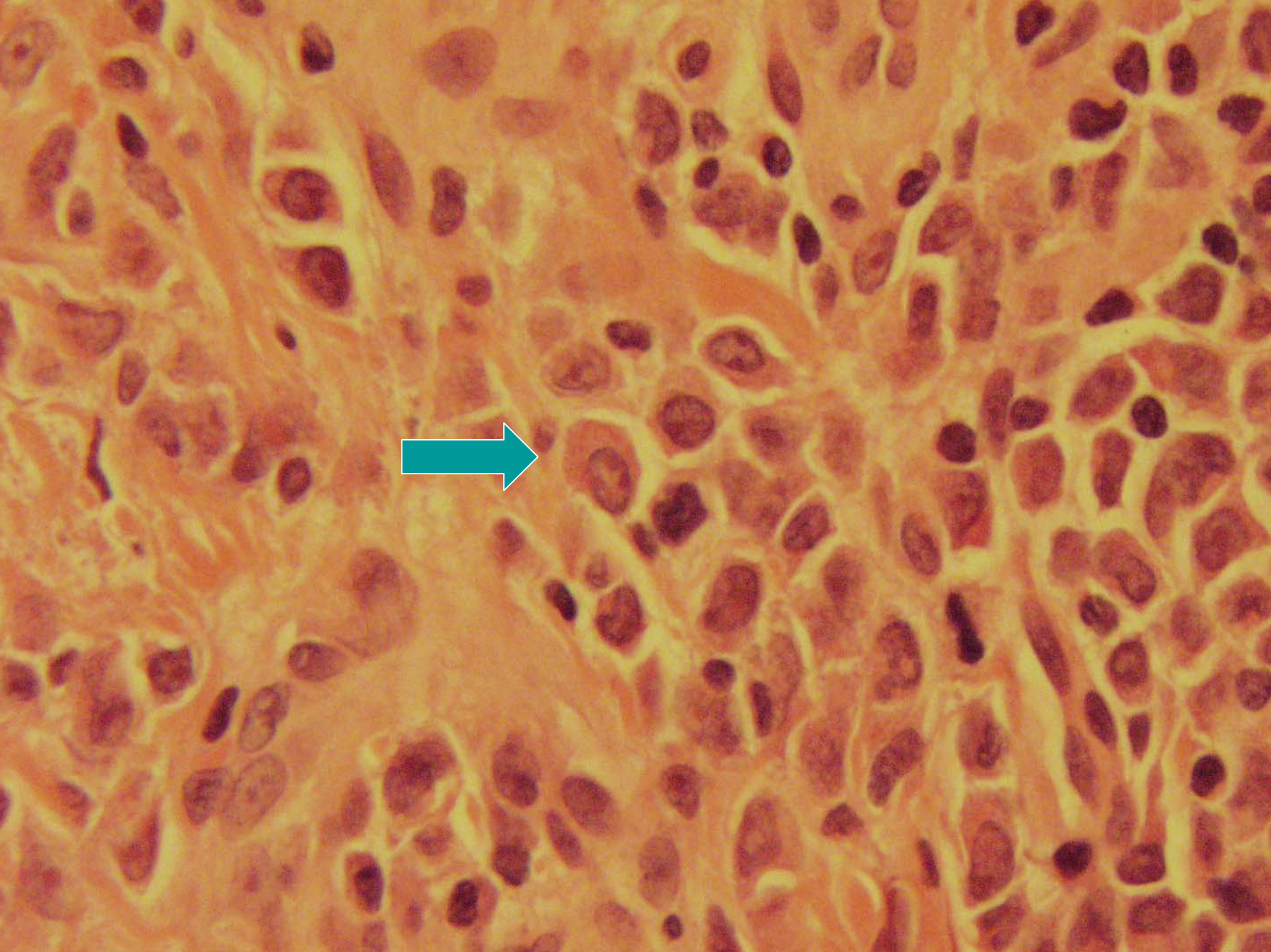











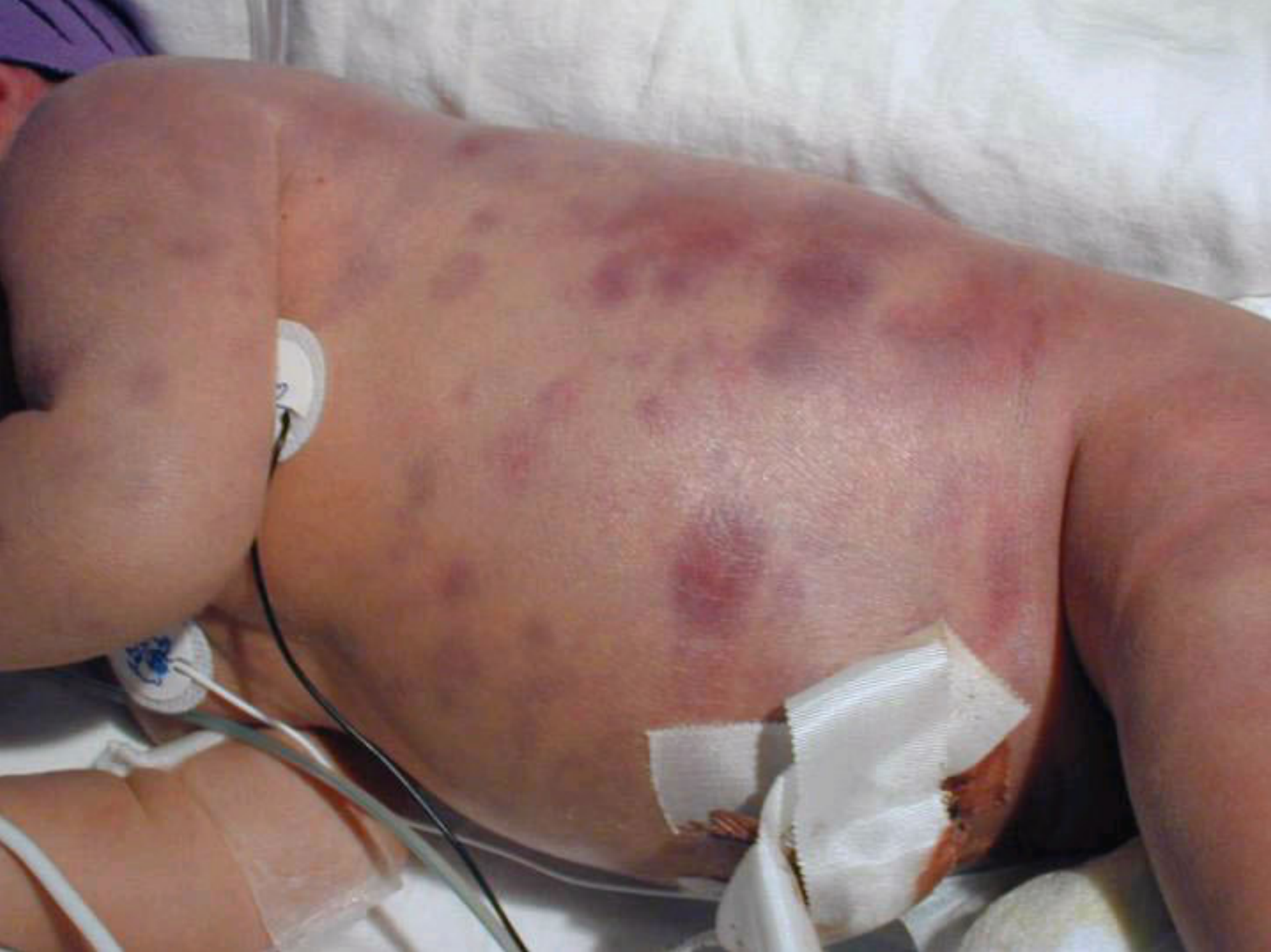


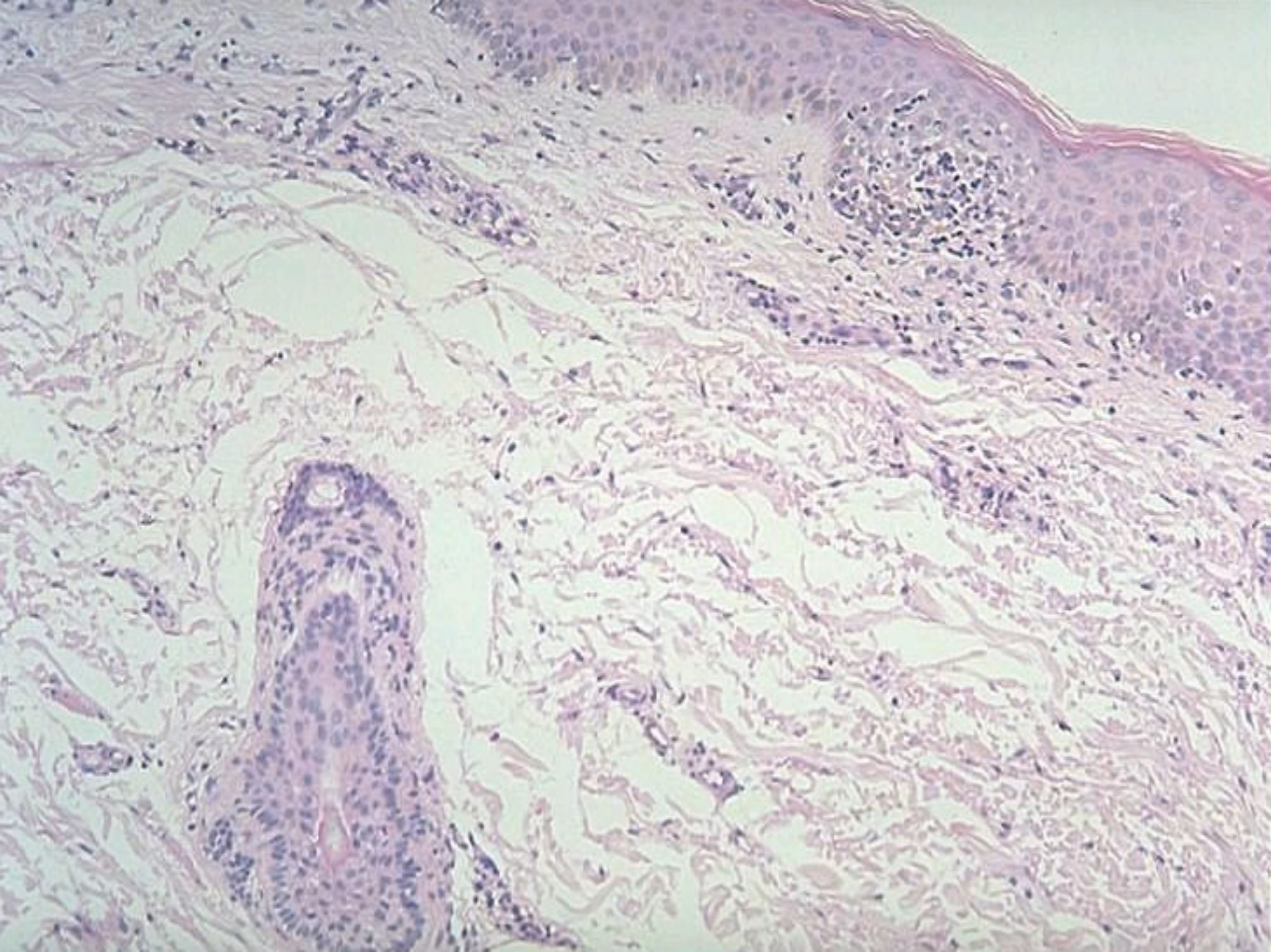
# Leukemia Cutis

- Morphology dependent upon leukemia type
- Usually lacks epidermotropism
- Myeloid leukemias may have immature myeloid precursors
- Check CBC

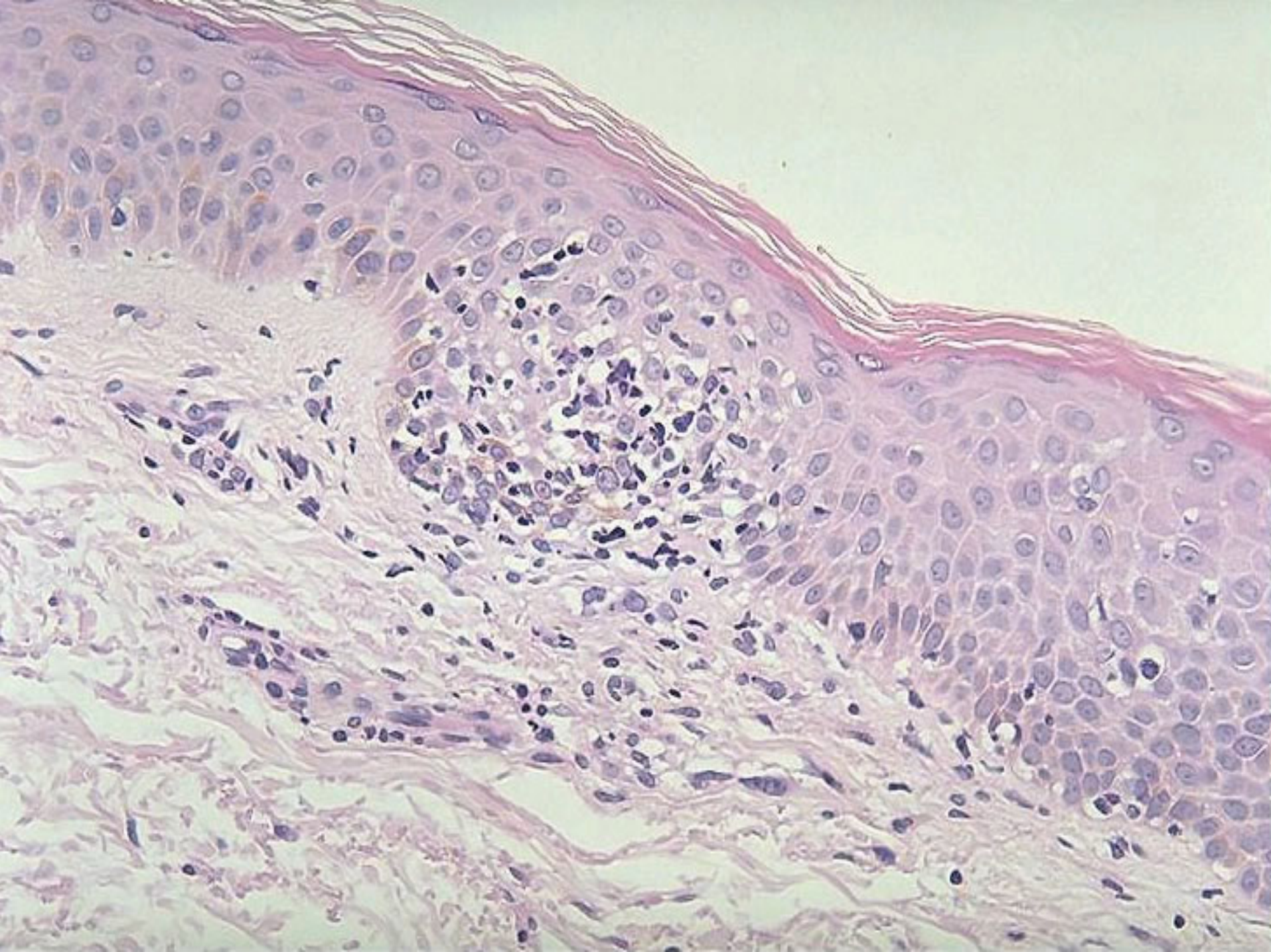




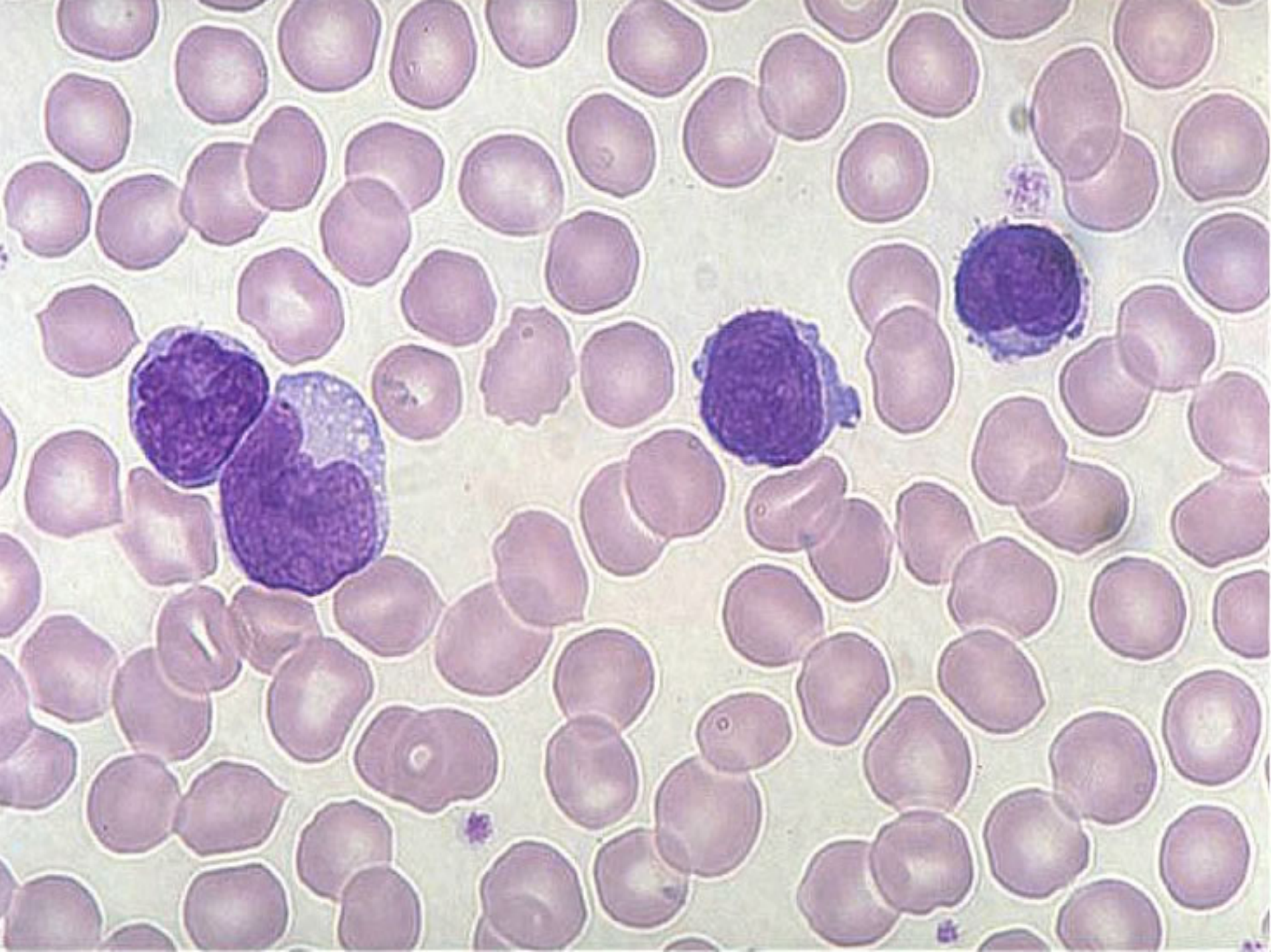














# Adult T-cell Leukemia/Lymphoma

- ATL predominant neoplastic cell phenotype was helper T-cell:
  - CD3+, CD4+, **L-selectin+**, **CD25+**, **CD45RA+**, HLA-DR+
  - **CD29-**, and **CD45RO-**
  - Peripheral blood, and CD3+, CD4+, L-selectin+, CD29+, CD45RO+, HLA-DR+, and CD45RA- in the skin and lymph nodes
- Predominant phenotype of CTCL
  - CD3+, CD4+, CD29+, CD45RO+, HLA-DR+, HLA-DQ+
  - CD7-, L-selectin-, and CD45RA-



# Adjuvant Studies

- IPOX
- Gene rearrangement



# Immunoperoxidase

- Usually CD4+
- Loss of CD7 followed by loss of CD2, CD5, or CD3
- Cases of MF (n = 17) with matching frozen tissue immunohistochemistry and benign reactive dermatoses (lichen planus; n = 27) were assessed for CD7 (Clone: CD7-272) deletion and TCR- PCR using paraffin-embedded biopsy specimens.
- Results: Excellent concordance comparing frozen and paraffin embedded CD7 immunostaining (88%) was observed. CD7 deletion and TCR- PCR was sensitive (94%) and specific (96%) for a diagnosis of MF using paraffin-embedded biopsy specimens.
- Conclusion: In the diagnosis of MF, detection of CD7 deletion and monoclonal TCR rearrangements can be successfully performed in a cost-effective, timely fashion using routine formalin-fixed paraffin-embedded biopsy specimens.



# Caveats for Loss of CD7

- Examined 22 cases of MF and 61 controls, found minimal CD7 expression by lymphocytes in MF and in a few cases of benign inflammatory dermatosis (BID)
  - The lowest mean CD7 counts (as a percentage of total lymphocytes) were found in MF (patch stage: 5% +/- 5%, range: 0-10; plaque and tumor stages: 15% +/- 5%, range: 5-25), and these counts were significantly lower than those for BID (35% +/- 20%, range: 5-80;  $p = 0.001$ )
- Low CD7 expression (<10% lymphocytes labeling) had sensitivity and positive predictive values of 80% and 72%, respectively, and specificity and negative predictive values of 93% and 96%, respectively, for the diagnosis of patch stage MF.
  - False-positive results were found for spongiotic dermatitis
  - Spongiotic dermatitides exhibited a progressive decrease in mean CD7 counts from acute to subacute to chronic stages (50% versus 35% versus 30%, respectively)
- Minimal CD7 expression is a specific finding for MF
  - Benign inflammatory infiltrates can also show low CD7 expression, however, which rarely matches that of patch stage MF
  - Progressive loss of CD7 expression in BID is the likely consequence of expansion of antigen-selected CD3+CD4+CD7- T cells. These inflammatory CD4+CD7- T cells may represent the physiologic counterpart to the neoplastic lymphocyte of MF.
- Am J Dermatopathol 2002 Feb;24(1):6-16



# Gene Rerrangement-Does it Make a Prognostic Difference?

- The detection of clonality by TSB correlates with a higher TNM stage (median stage for positive TSB, IIb vs negative TSB, Ib;  $P < .05$ ), but not with age at presentation (62 vs 59 years) or duration of disease before presentation (6.2 vs 5.9 years).
  - Although the long-term survival was not significantly different between the 2 groups, there was a trend for patients with positive TSB to die earlier (5-year survival of 67% vs 87%). Disease progression did not correlate with TSB results.
  - Higher clonality rates were noted among patients with biopsy specimens showing a denser lymphoid infiltrate and a higher grade of cytologic atypia.
- Detection of clonality with TSB requires a significant clonal burden. Although clonality can be detected in patients with patches and plaques (T1 and T2) most cases with positive results were obtained from patients with advanced disease (T3 and T4)
- Conclusion: Detection of clonality by TSB does not correlate with disease progression and does not carry long-term prognostic implications.



# Gene Rearrangement

- Histologic features of the 100 patients were first reviewed by two independent dermatopathologists and their confidence in the diagnosis of CTCL was assigned one of four levels
  - Analyzed for TCR gene rearrangement either on paraffin-embedded or fresh-frozen tissue by PCR/denaturing gradient gel electrophoresis (DGGE)
- Clonality detected:
  - 100% (15/15) diagnostic of
  - 84.6% (11/13) consistent with
  - 57.6% (19/33) suggestive of CTCL
  - 9 cases TCR gene rearrangement was compared between formalin-fixed and fresh specimens of the same individual, but with different degrees of histologic confidence (no lower than suggestive)
    - In all cases fresh specimens were positive
    - In 5 of the cases (2-diagnostic, 2-consistent, 1-suggestive) formalin-fixed specimens were positive as well, and in 4 cases (1-consistent, 3-suggestive) formalin-fixed specimens were negative



# Gene Rearrangement

- TCR gene rearrangement was studied in eight cases on sequential biopsies from the same patient
  - Clonality was detected in only one or two biopsies in four cases in which the histologic confidence was low (suggestive or nondiagnostic)
  - TCR gene rearrangement study showed identical banding patterns in lesions from different clinical stages in most patients.
- One case, oligoclonal-banding pattern was seen in initial biopsy with histopathologic consistent with CTCL, while monoclonal banding pattern in more advanced lesion.
- Conclusions:
  - TCR gene rearrangement studies by PCR/DGGE are consistently positive regardless of tissue fixation (formalin-fixed, paraffin-embedded vs. fresh-frozen tissue) and biopsy site when the histologic degree of confidence is very high (diagnostic).
  - May be of less importance as an adjuvant to histopathologic diagnosis for the cases with diagnostic CTCL histology
  - TCR gene rearrangement studies are particularly important in earlier cases with less conclusive histology, which provides strong confirmatory evidence of an evolving CTCL
    - Multiple biopsies may be required to establish the diagnosis and analysis of fresh tissue is suggested to increase the sensitivity
    - Some CTCL might not be monoclonal de novo, but oligoclonal instead

# Additional References

- J Cutan Pathol 2001;28 (4):169-173.